

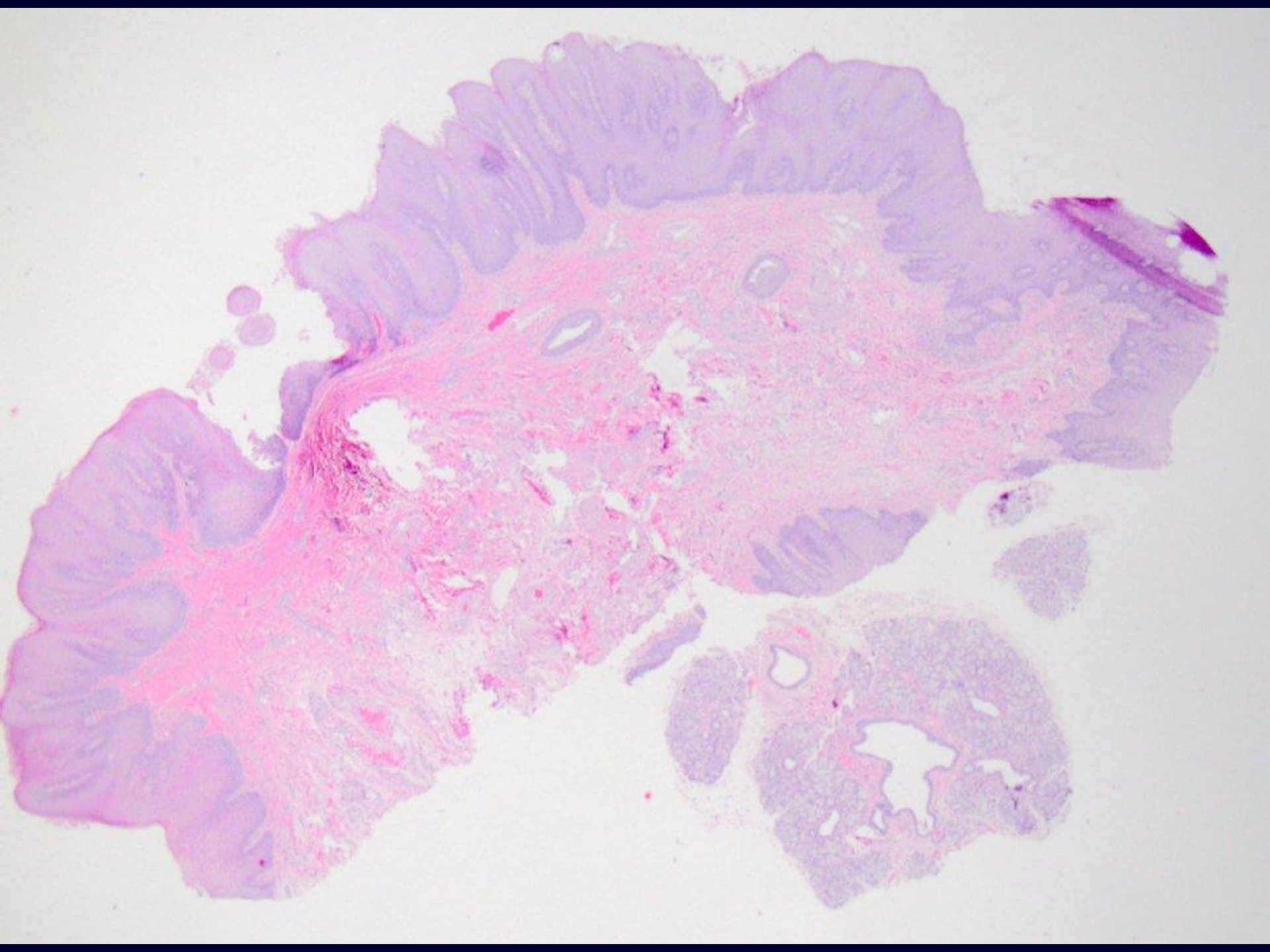
# Oral Histopathology

## Series 35

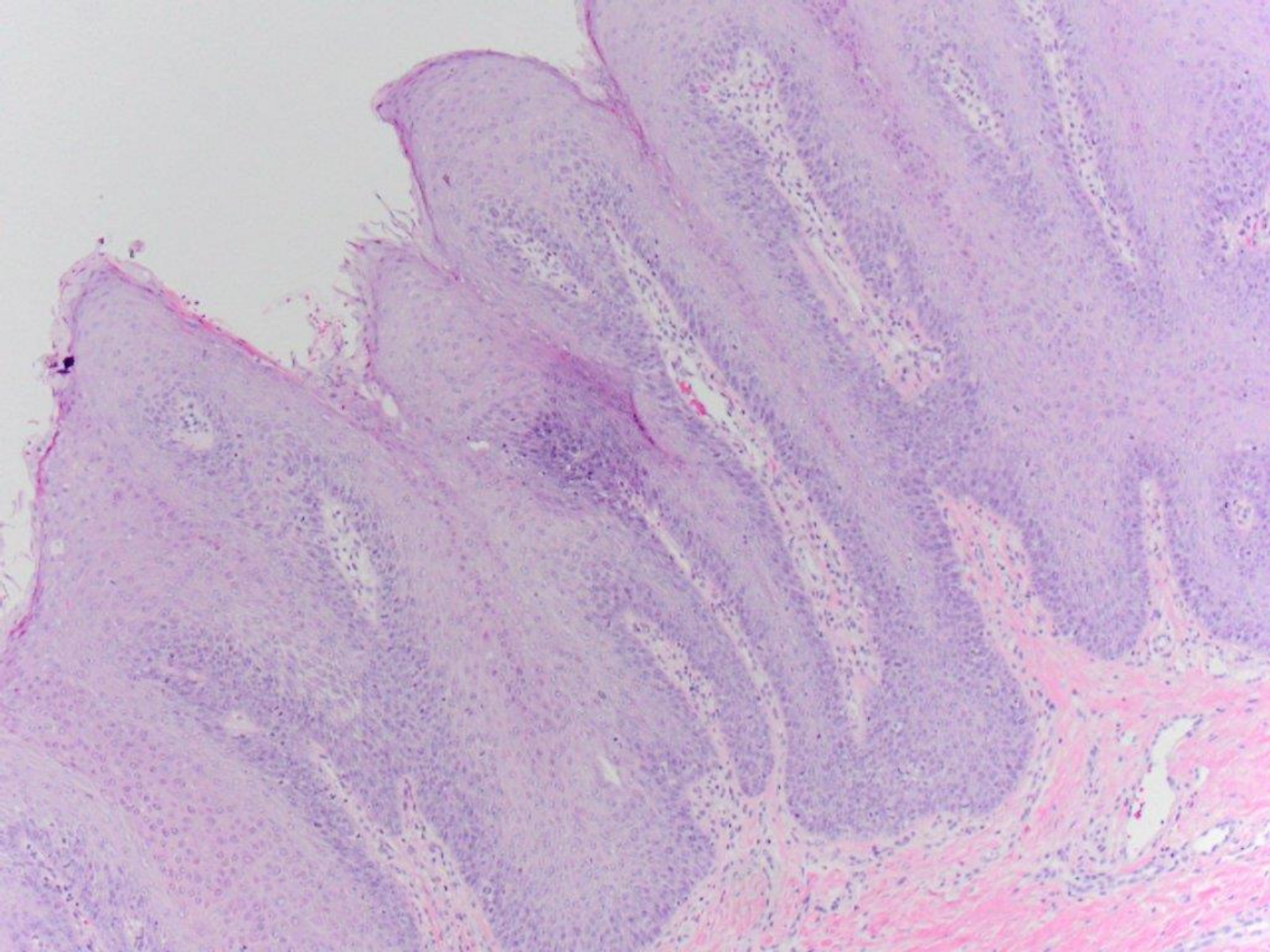
**DAVID E. KLINGMAN, DMD**

*Diplomate, American Board of Oral and Maxillofacial Pathology*

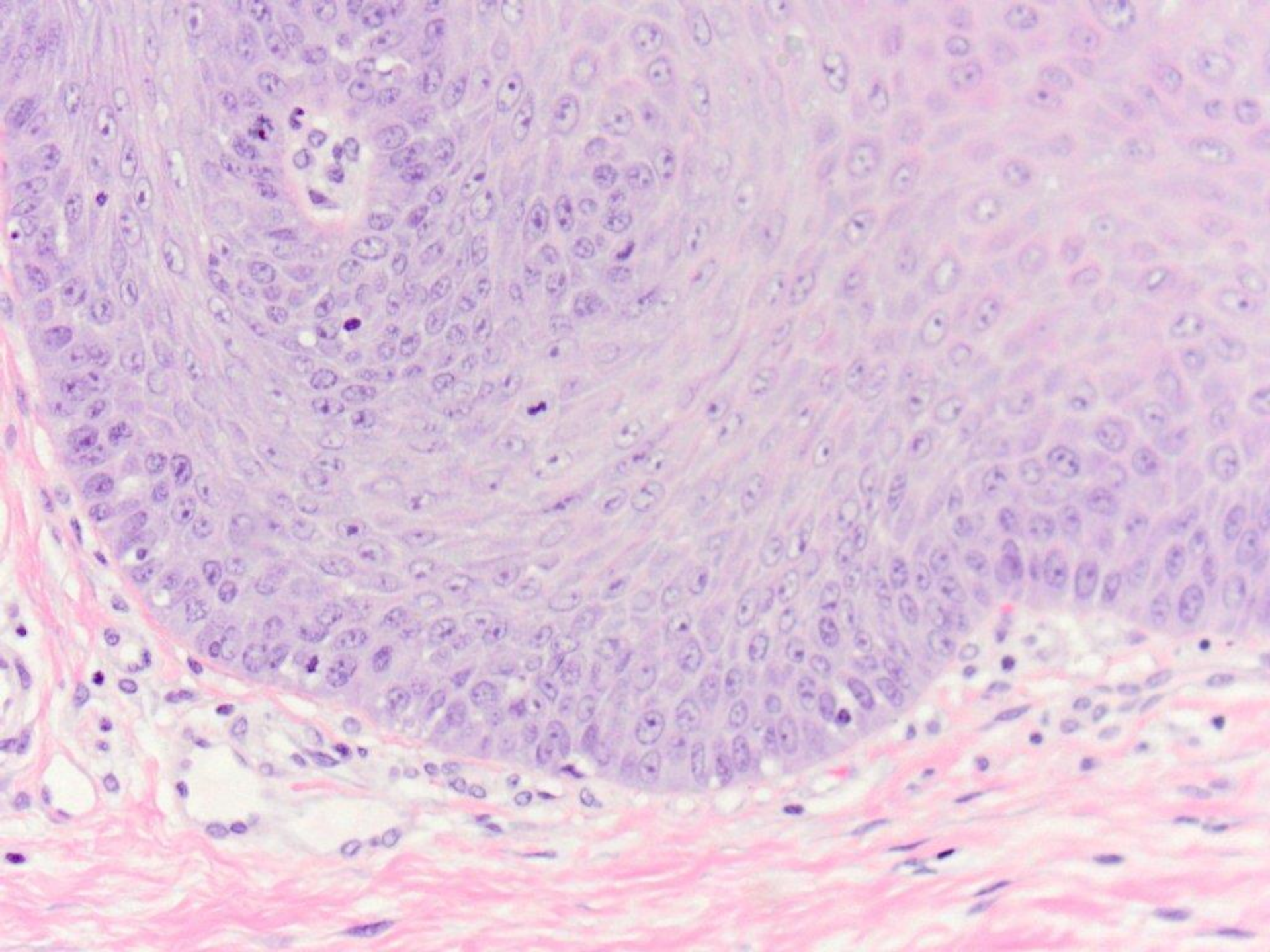
*Diplomate, American Board of General Dentistry*



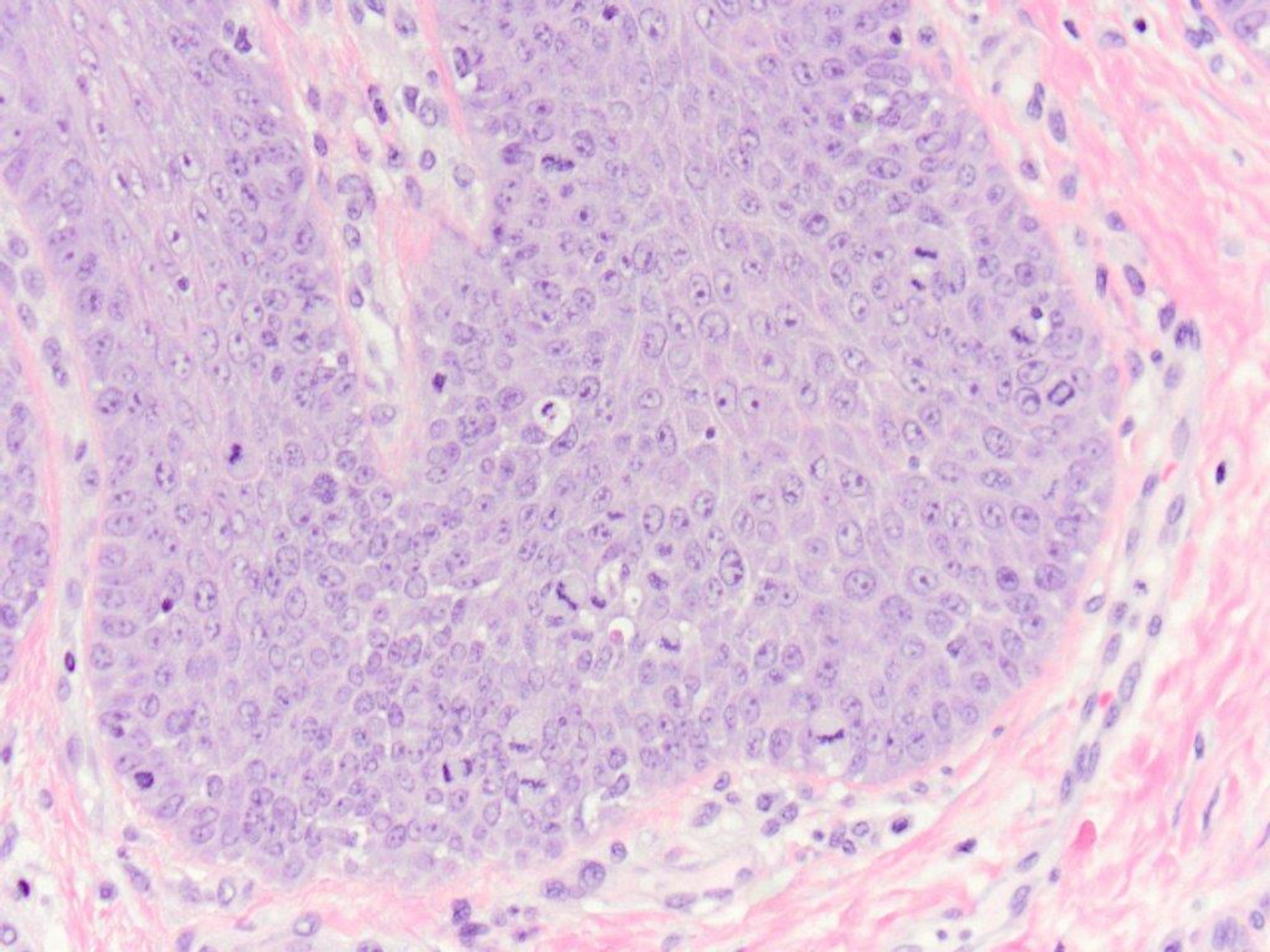




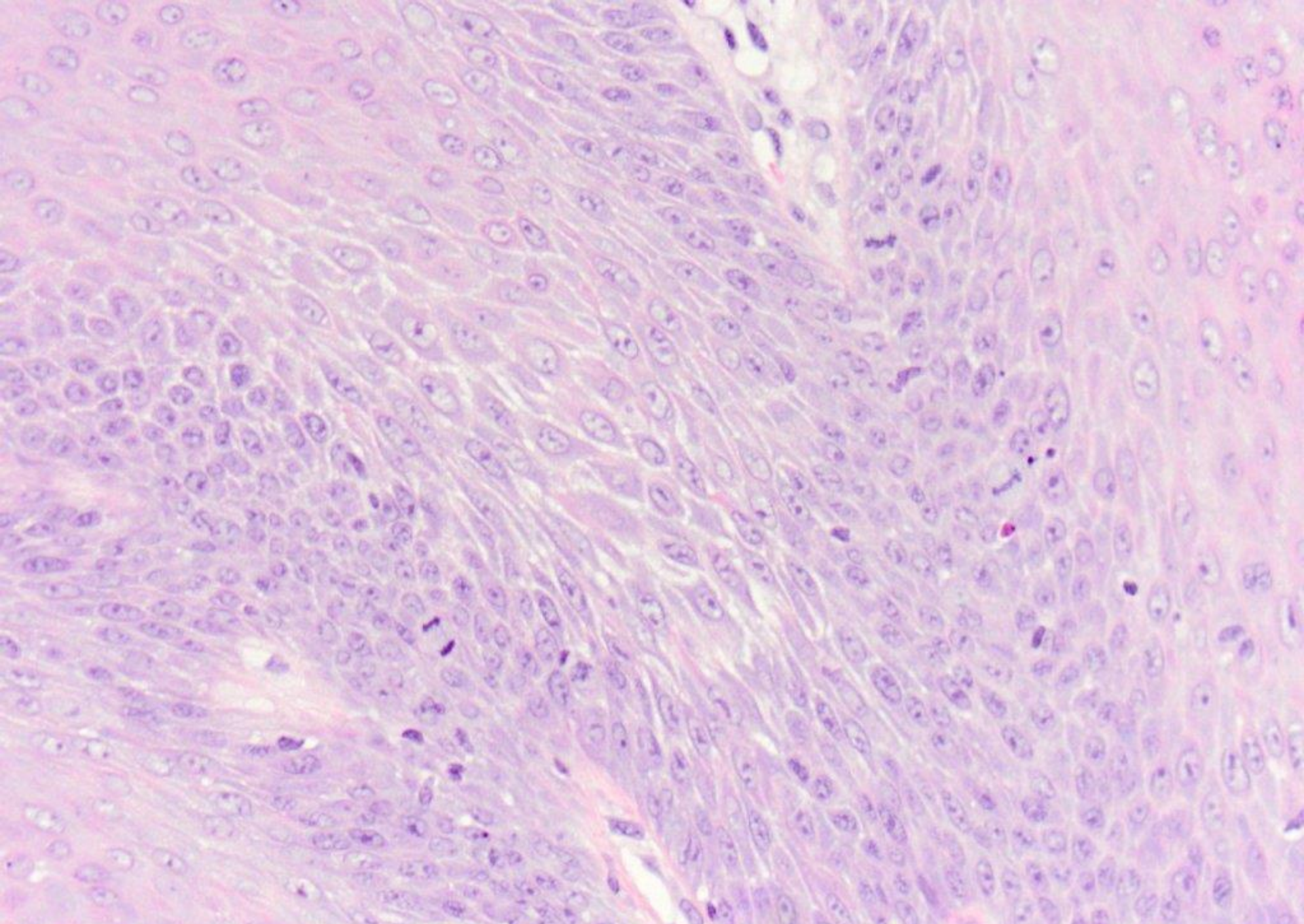






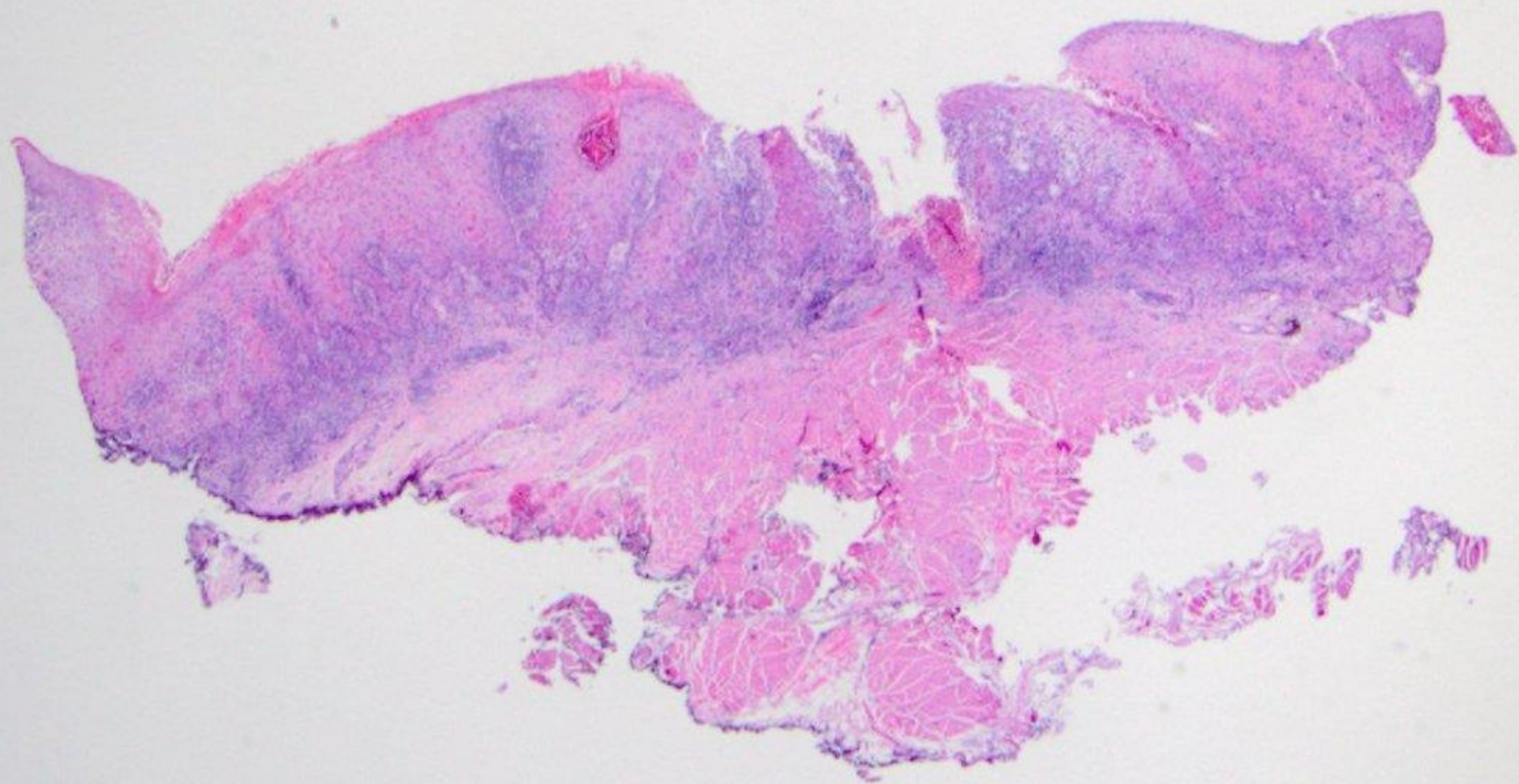


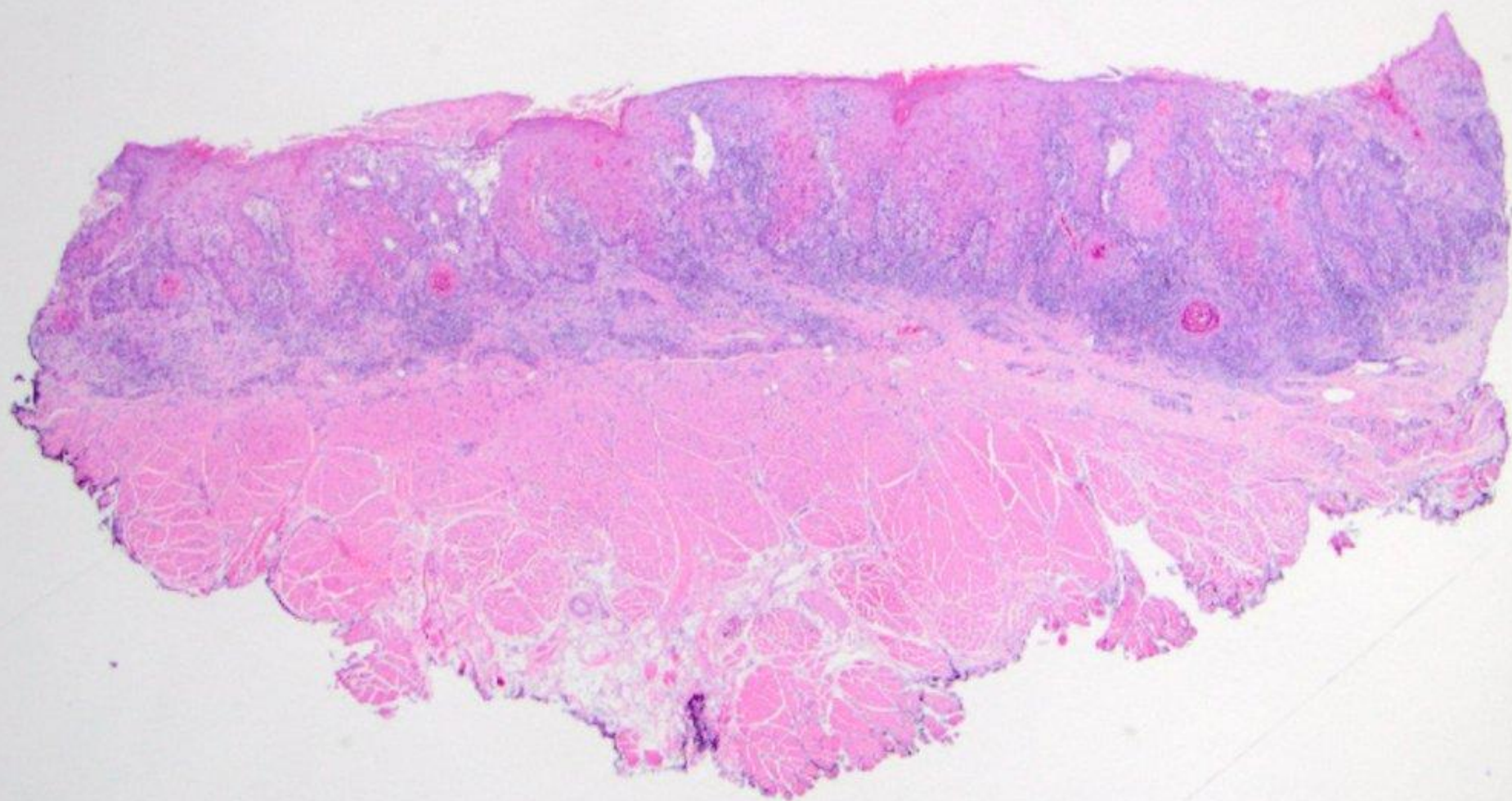




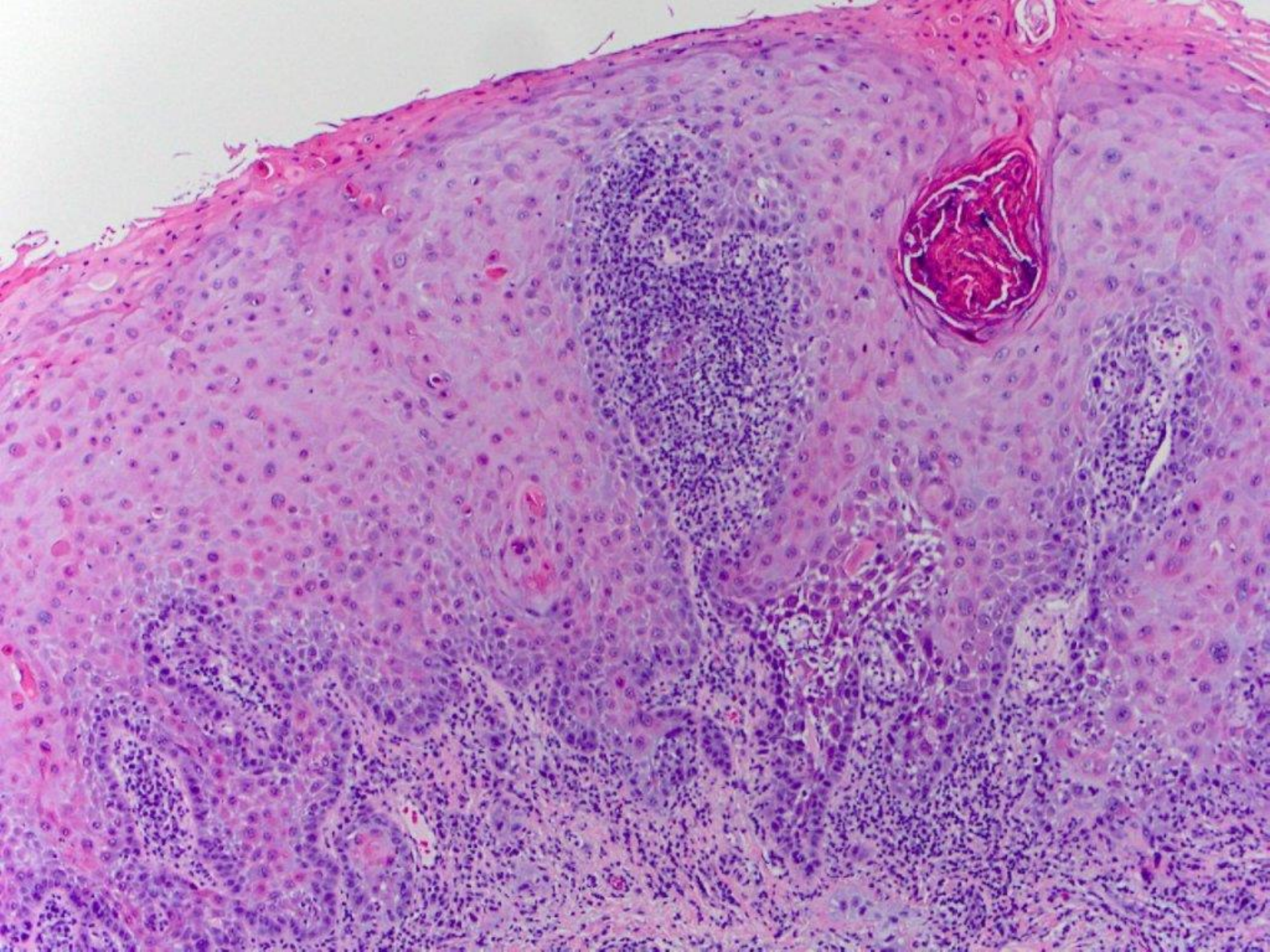
atypical verrucous hyperplasia in a background of mild to moderate dysplasia



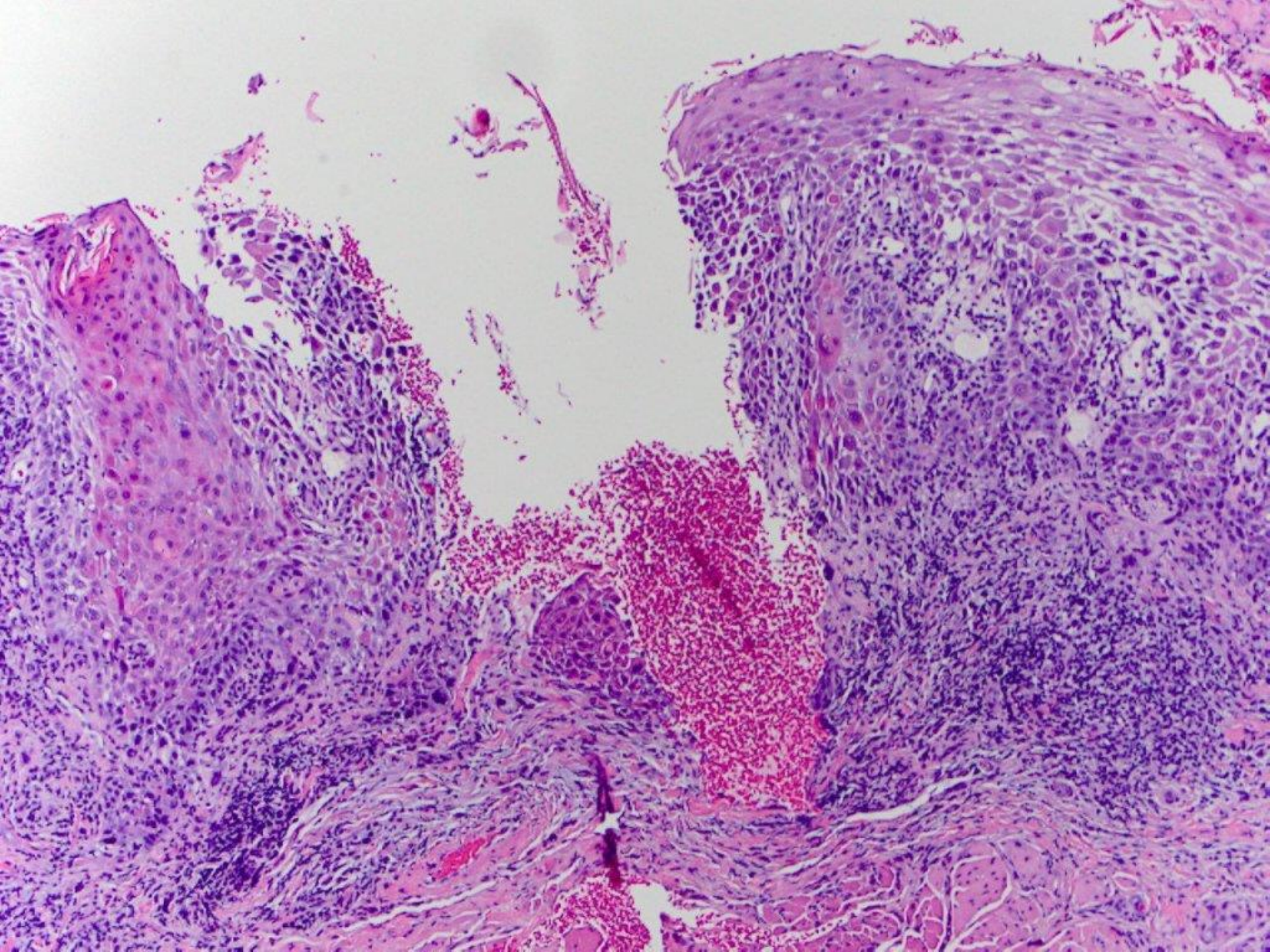




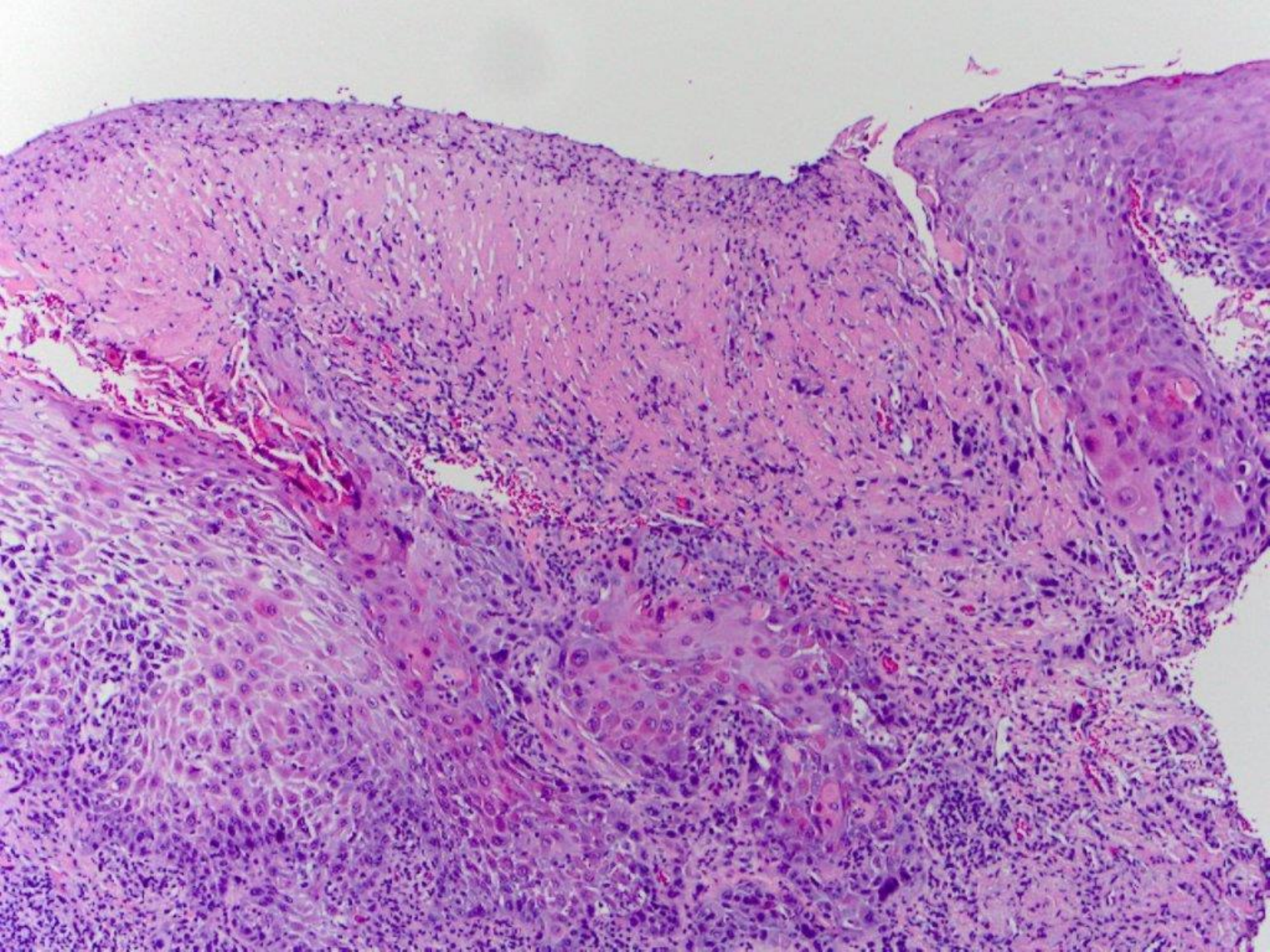




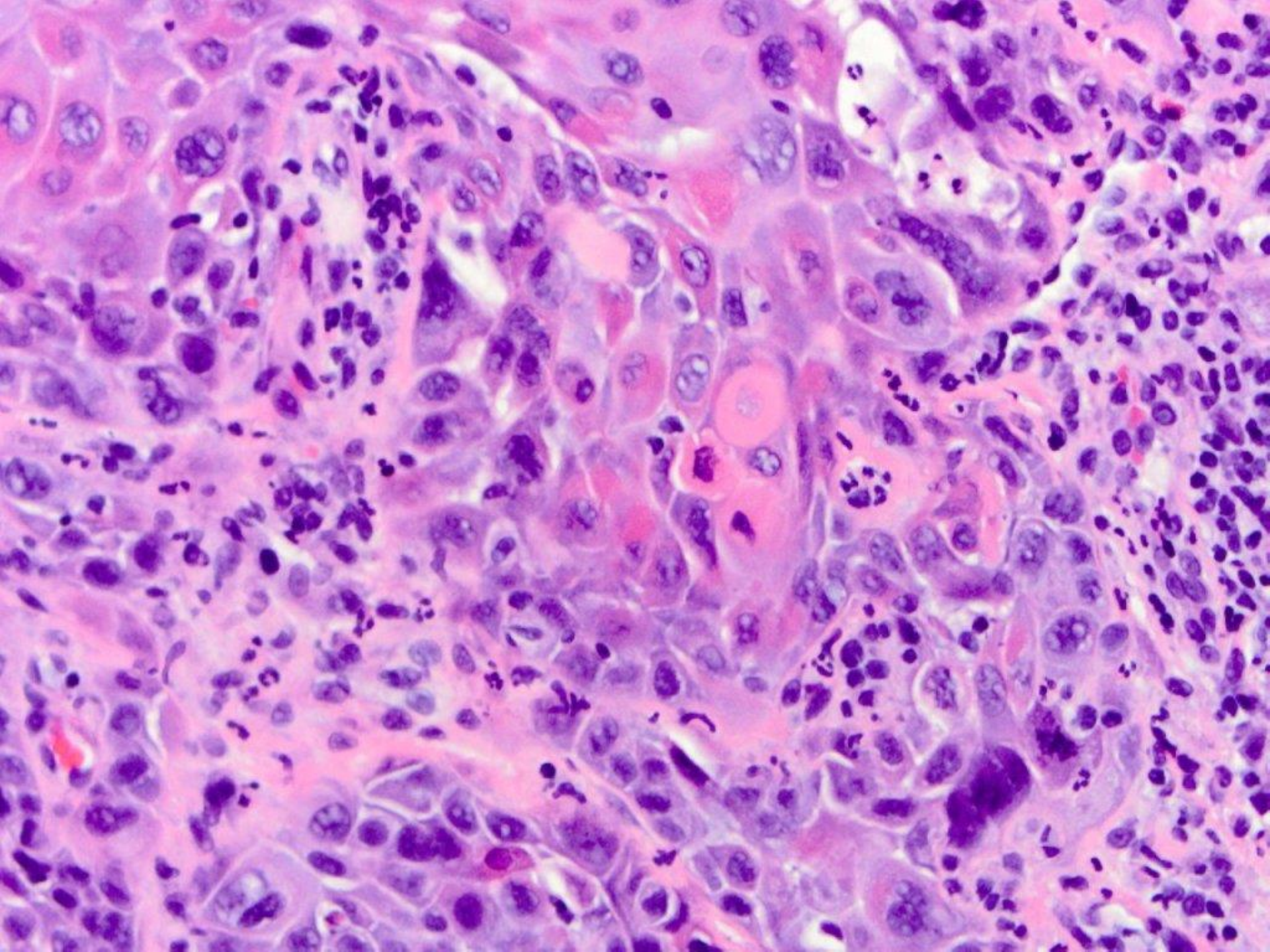




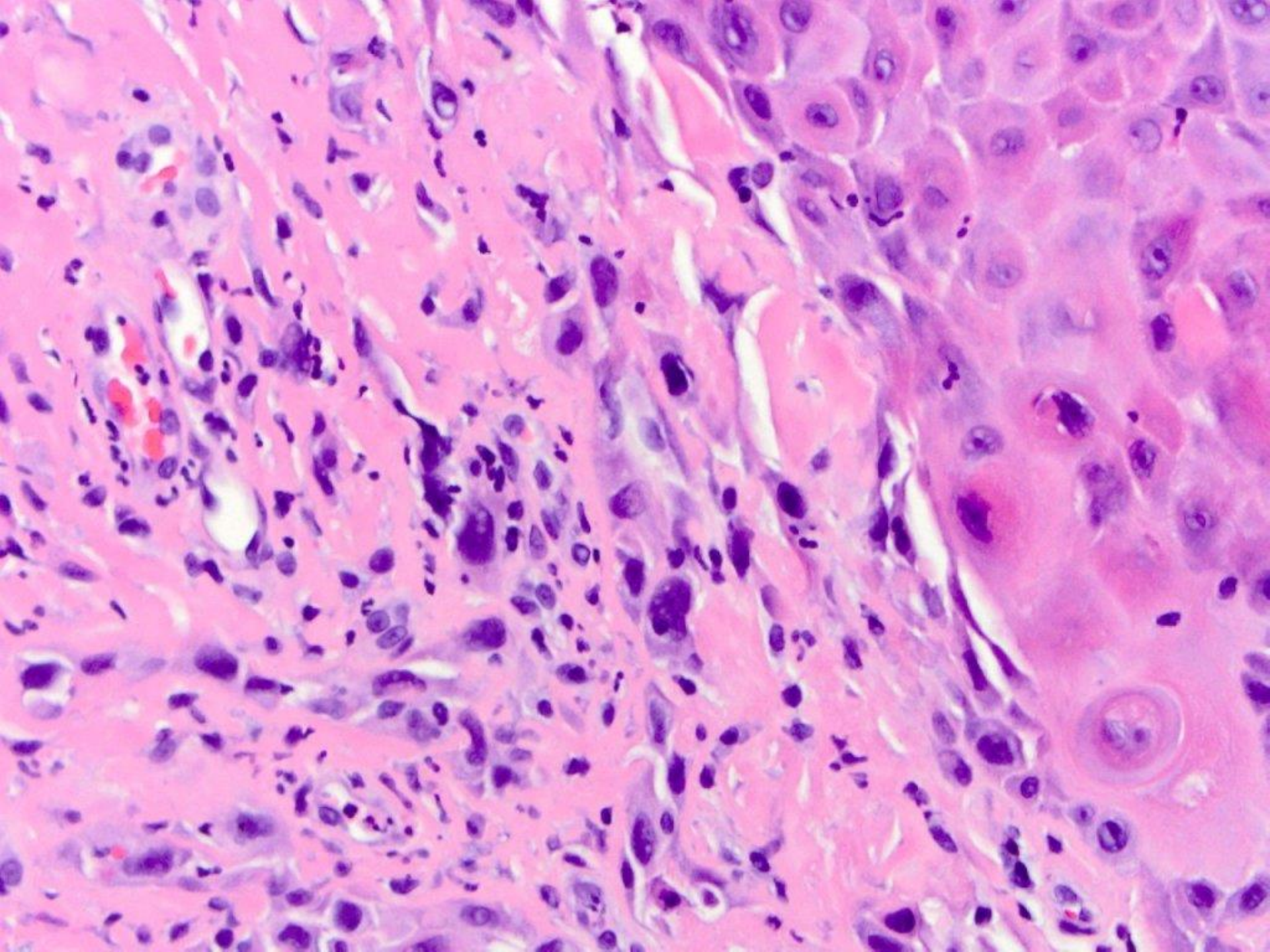




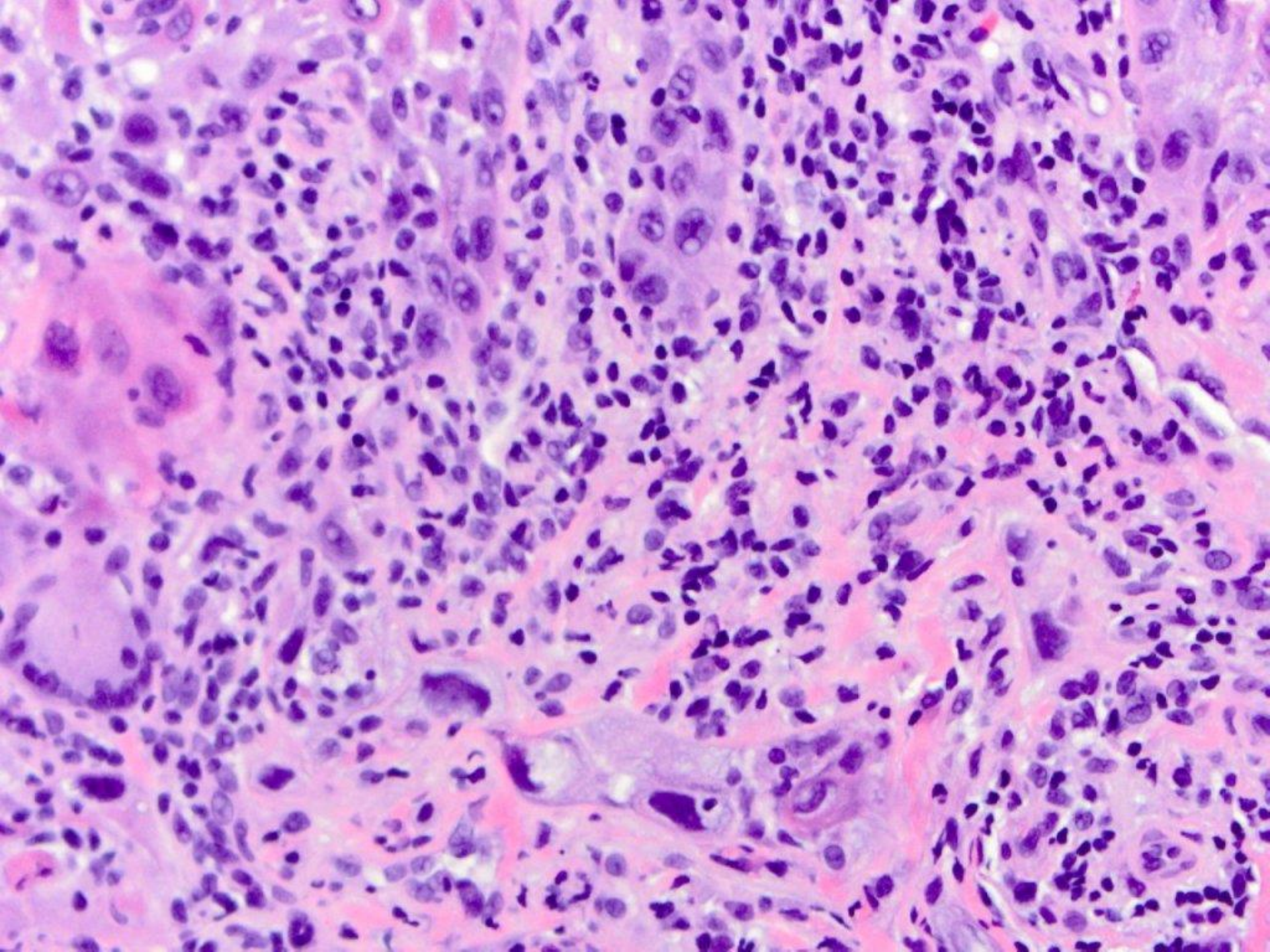




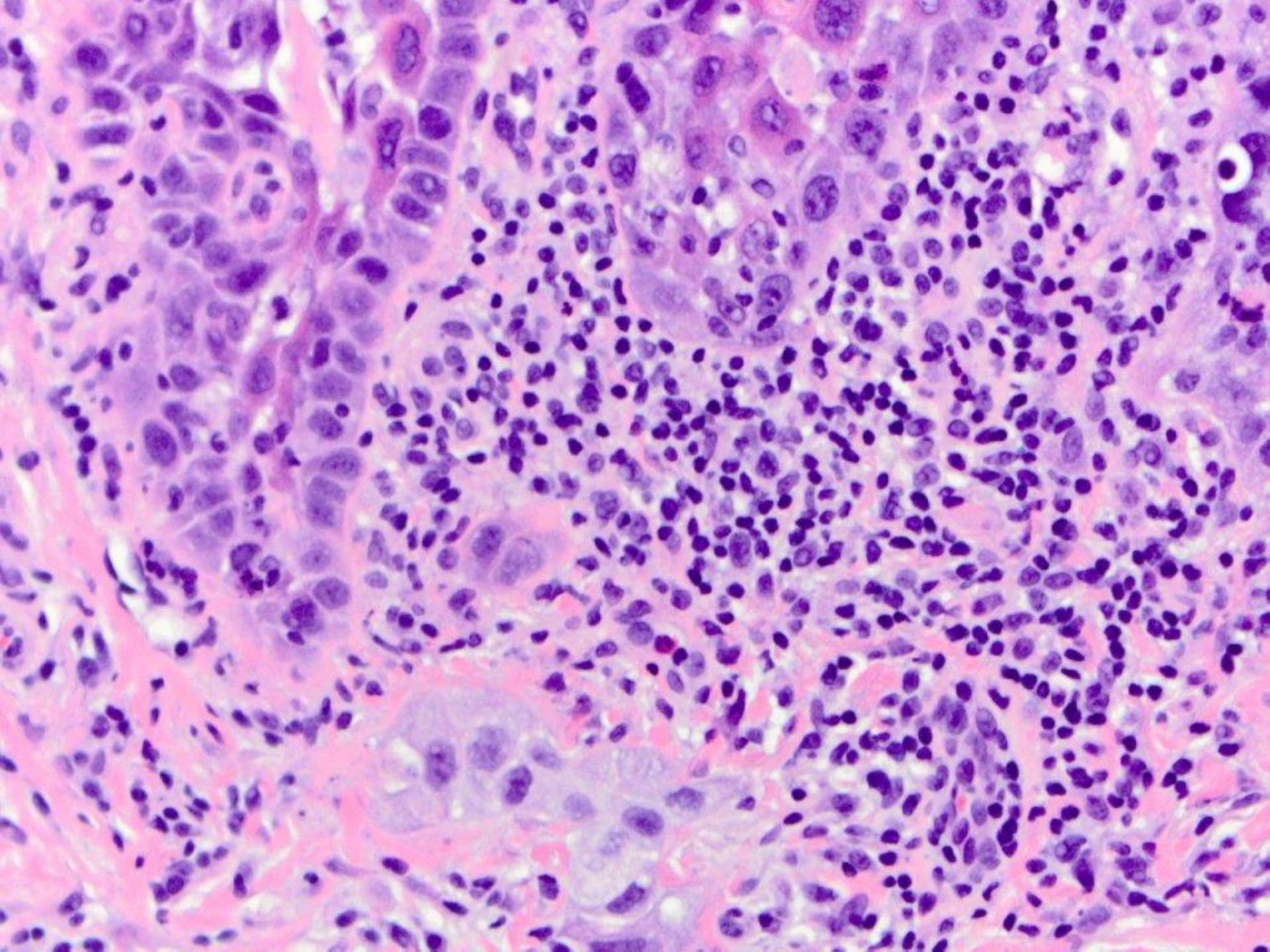




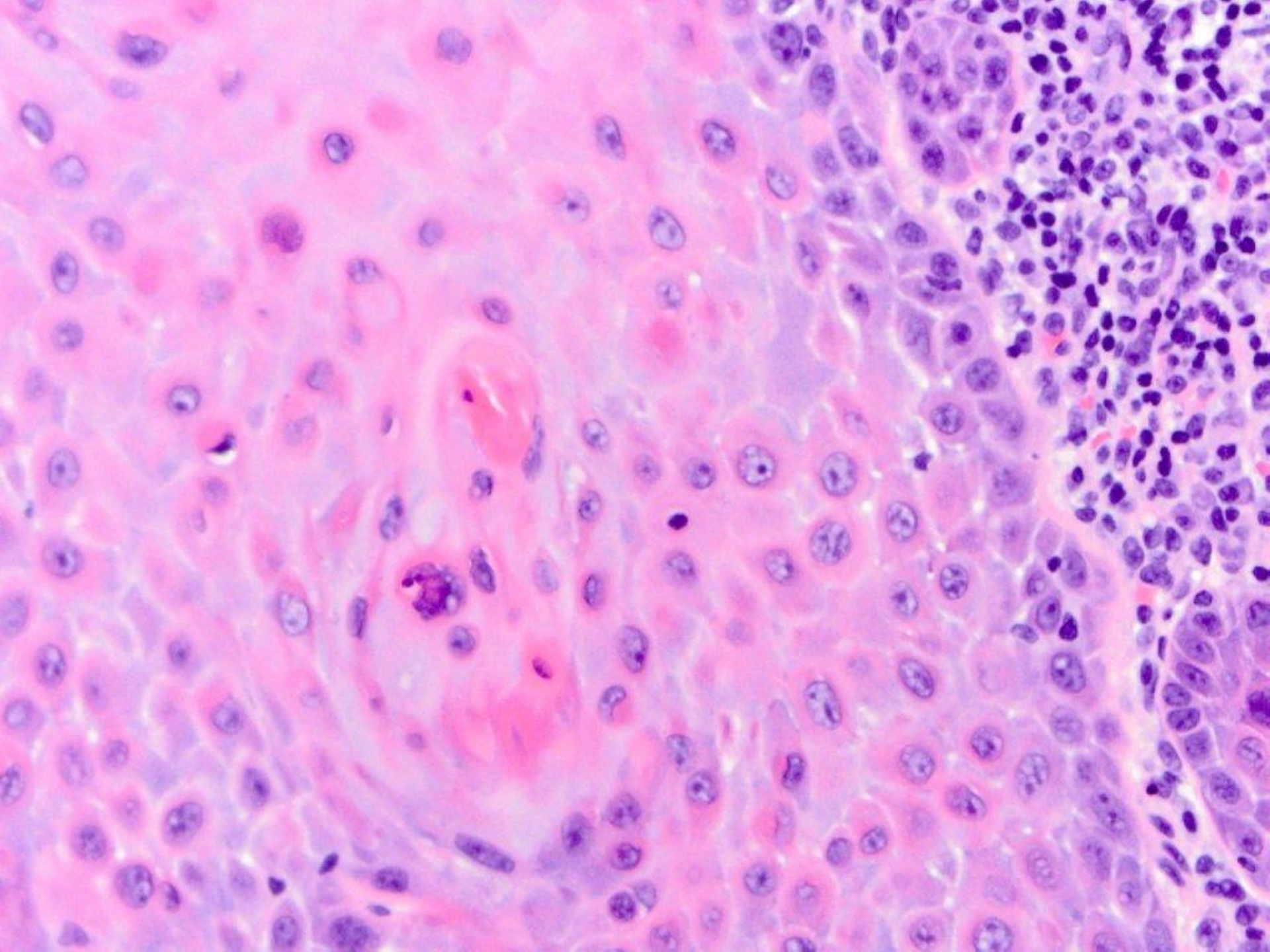




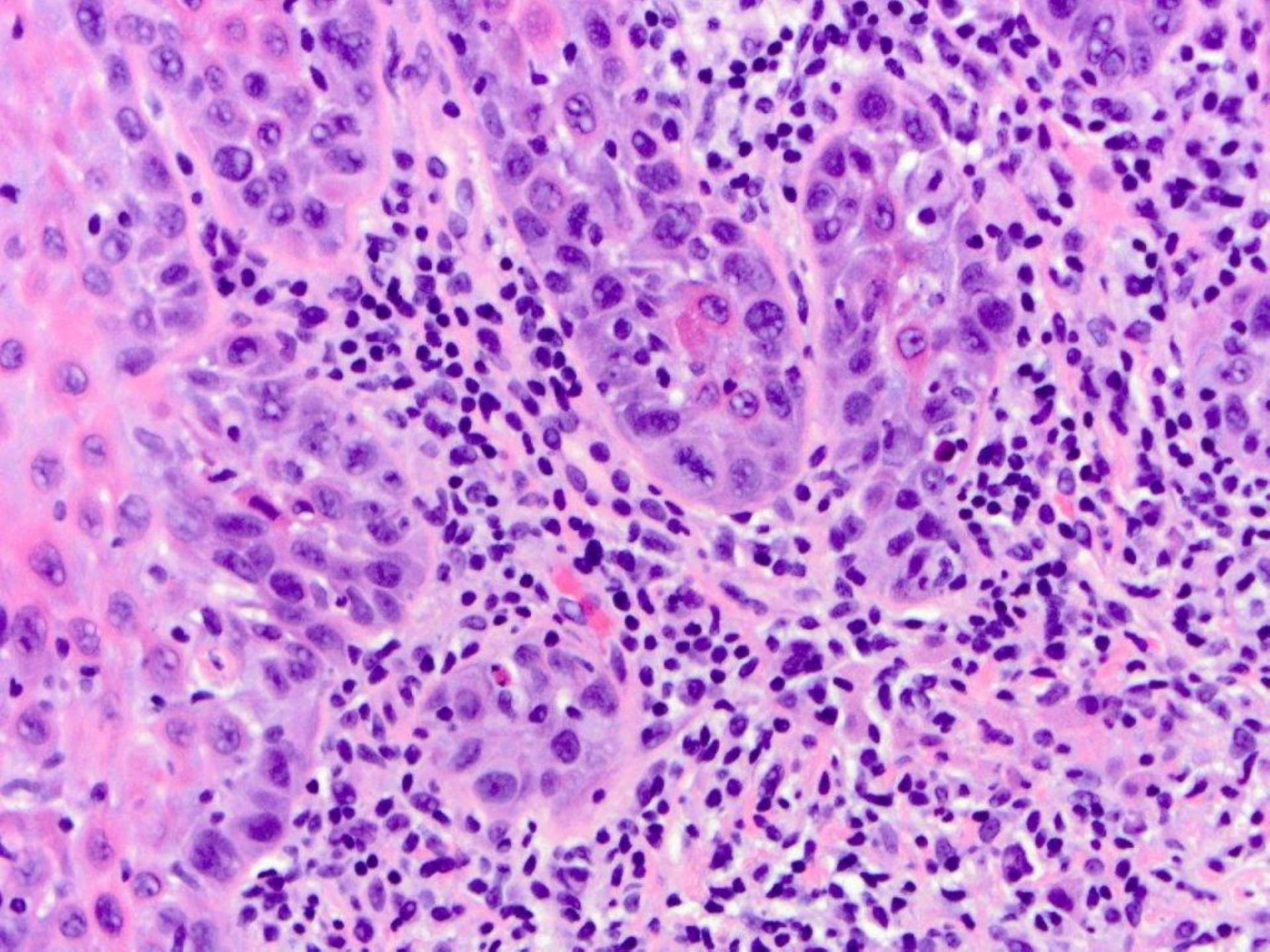




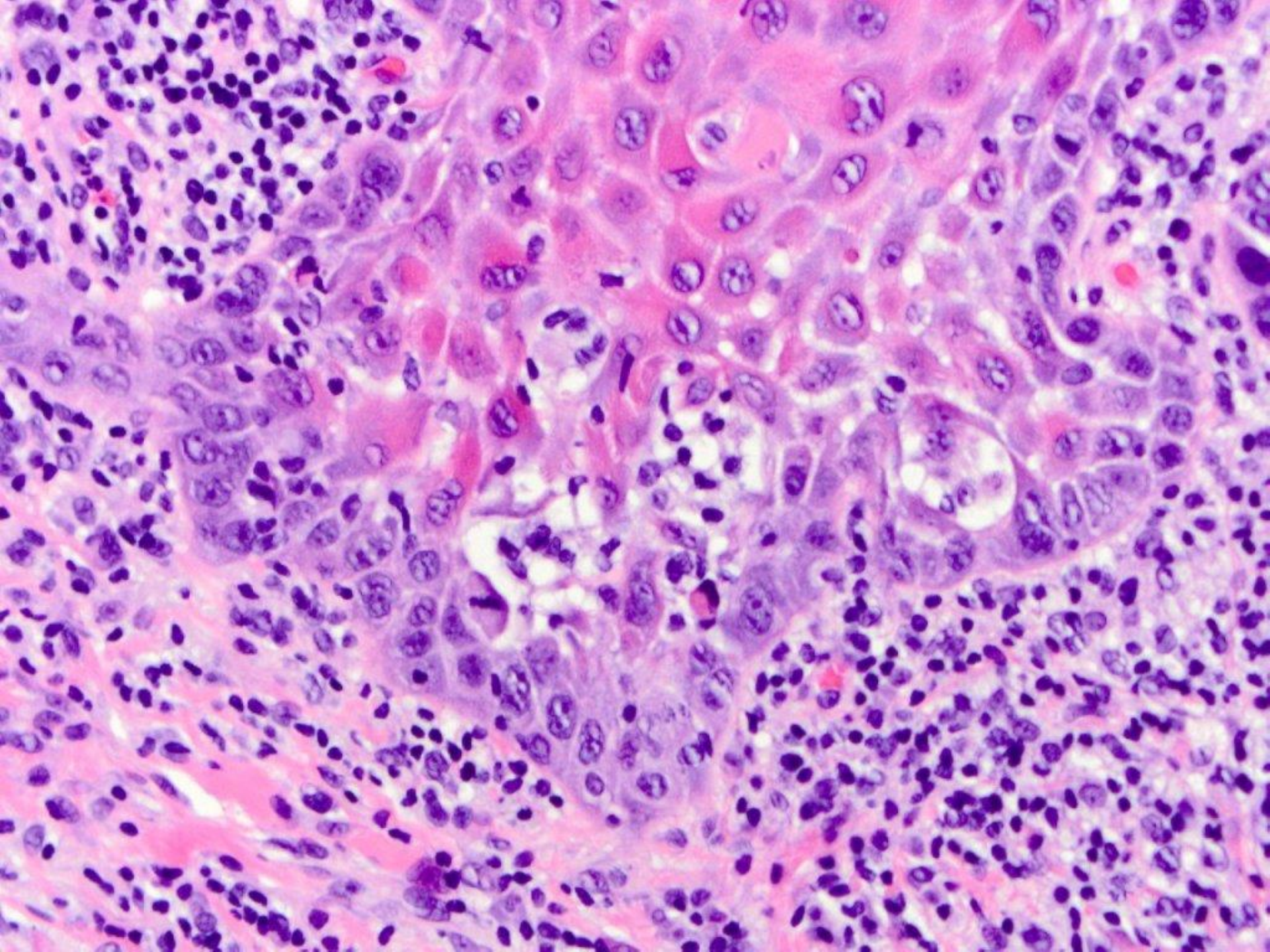




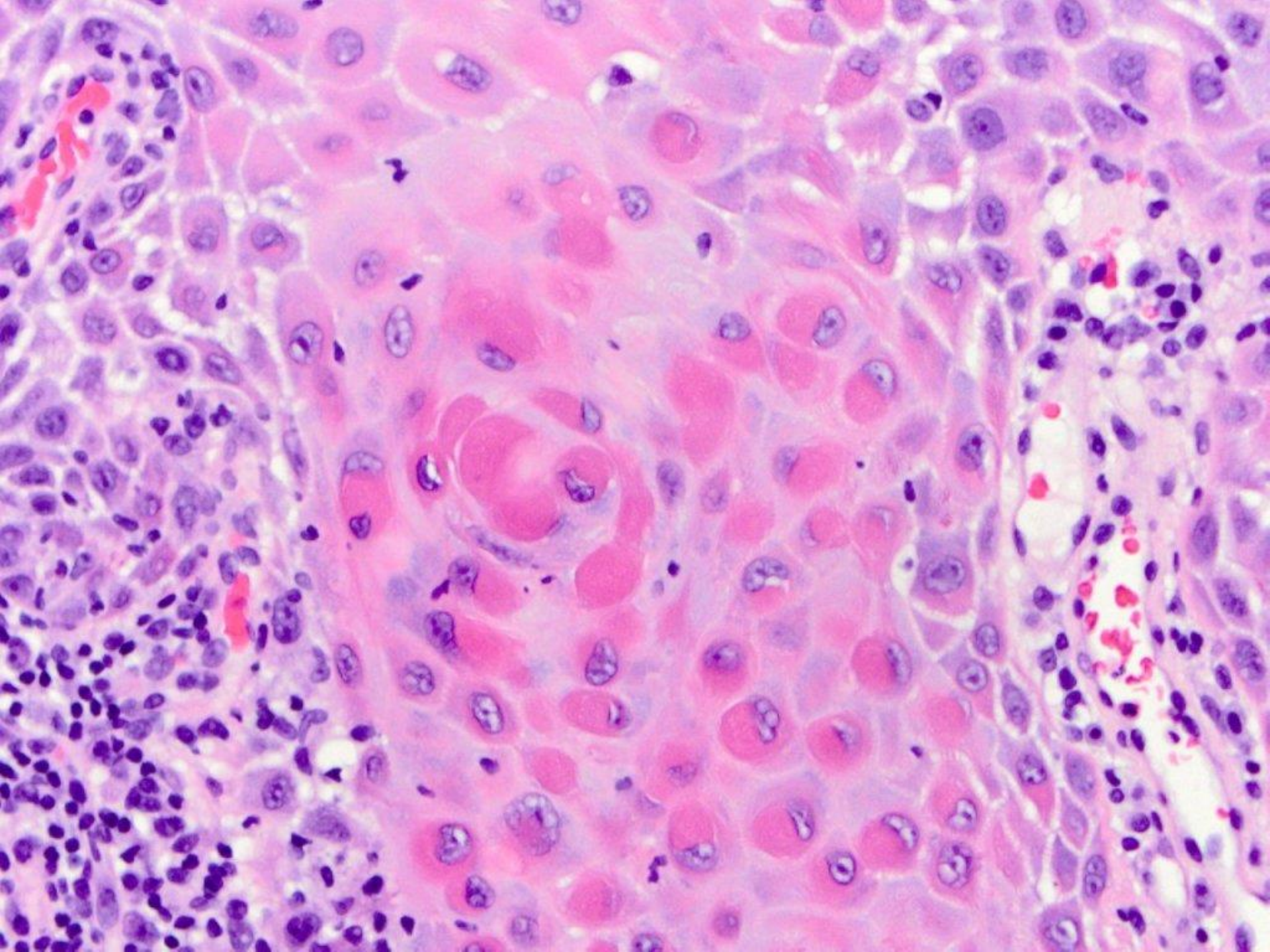




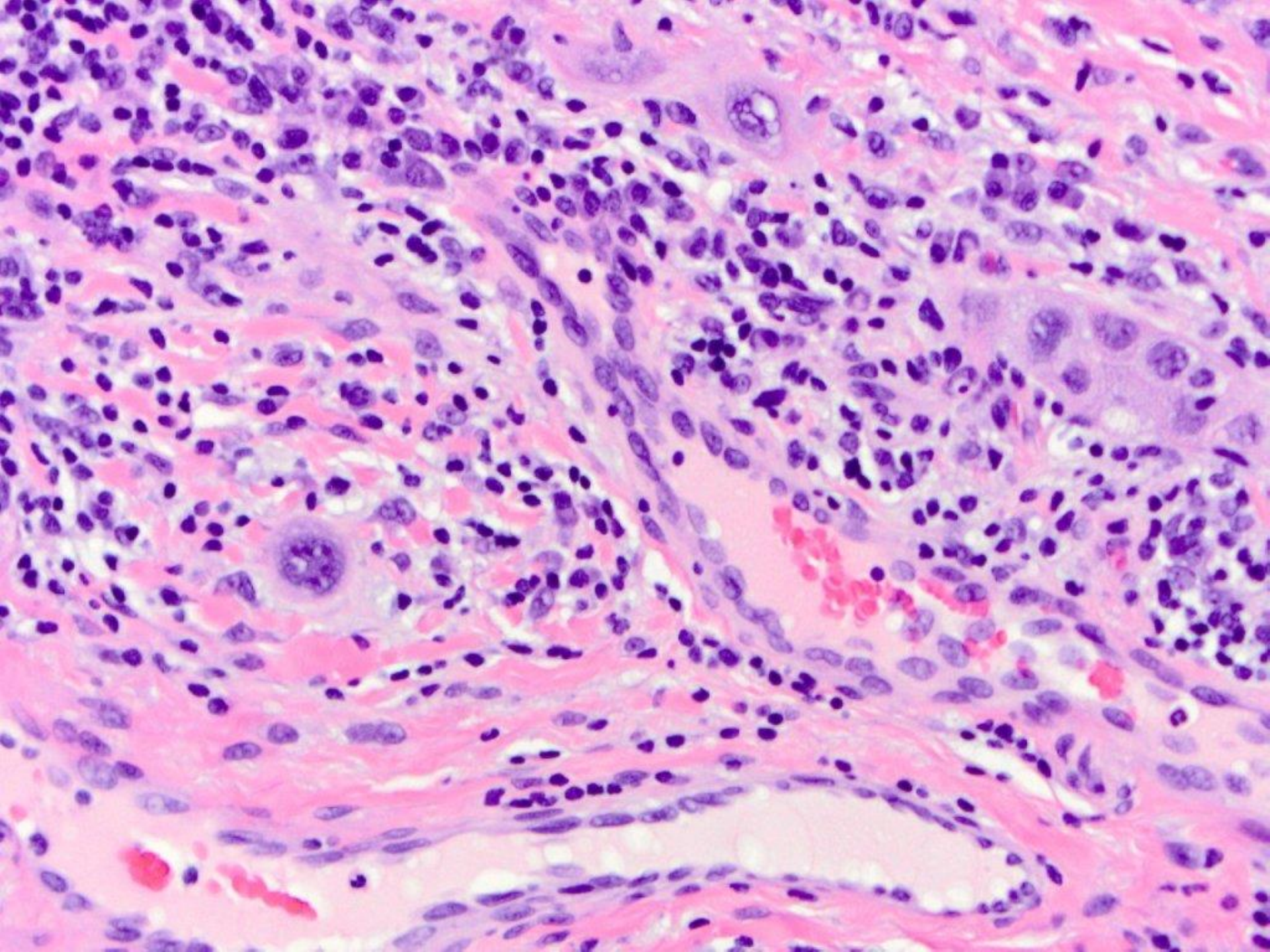




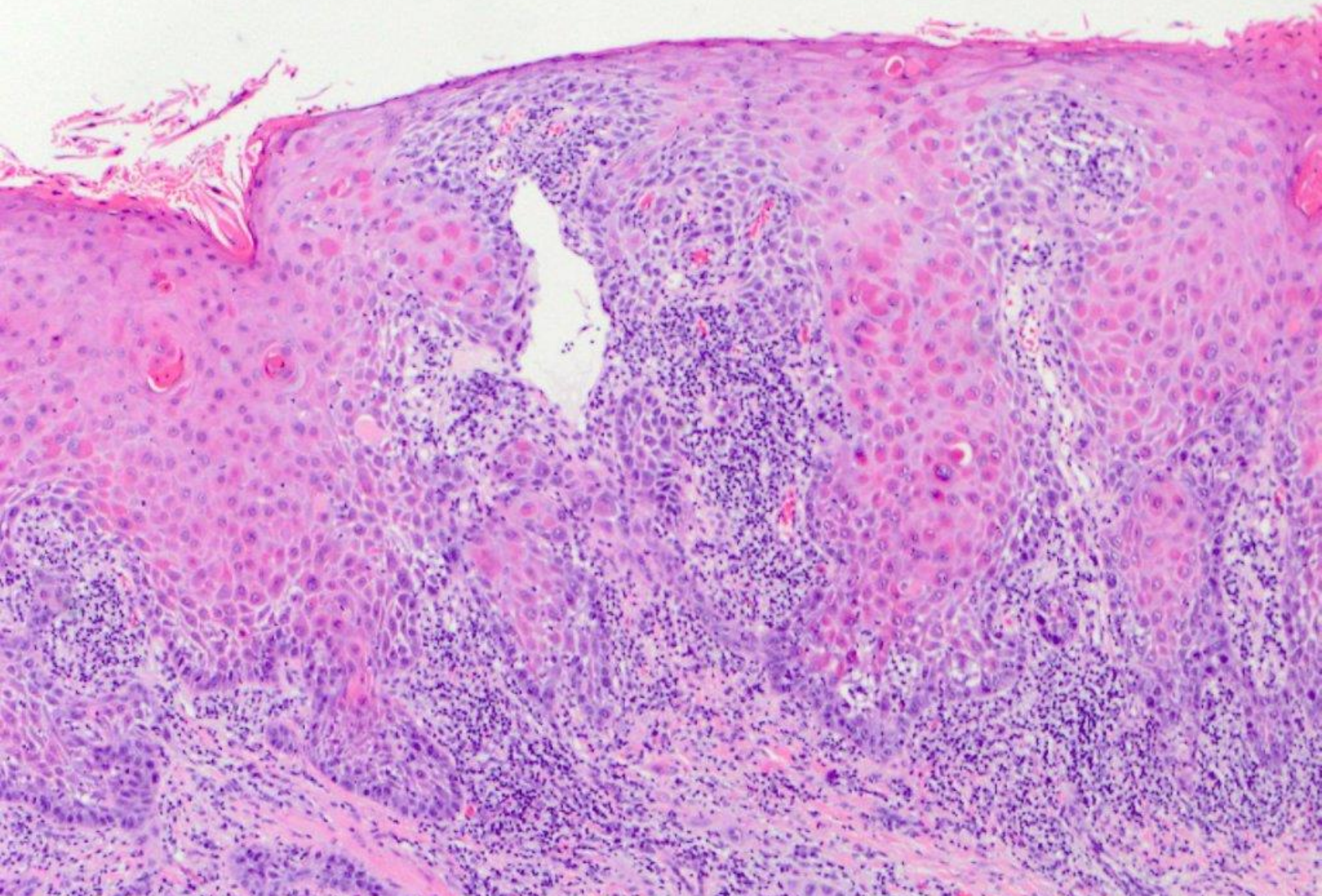






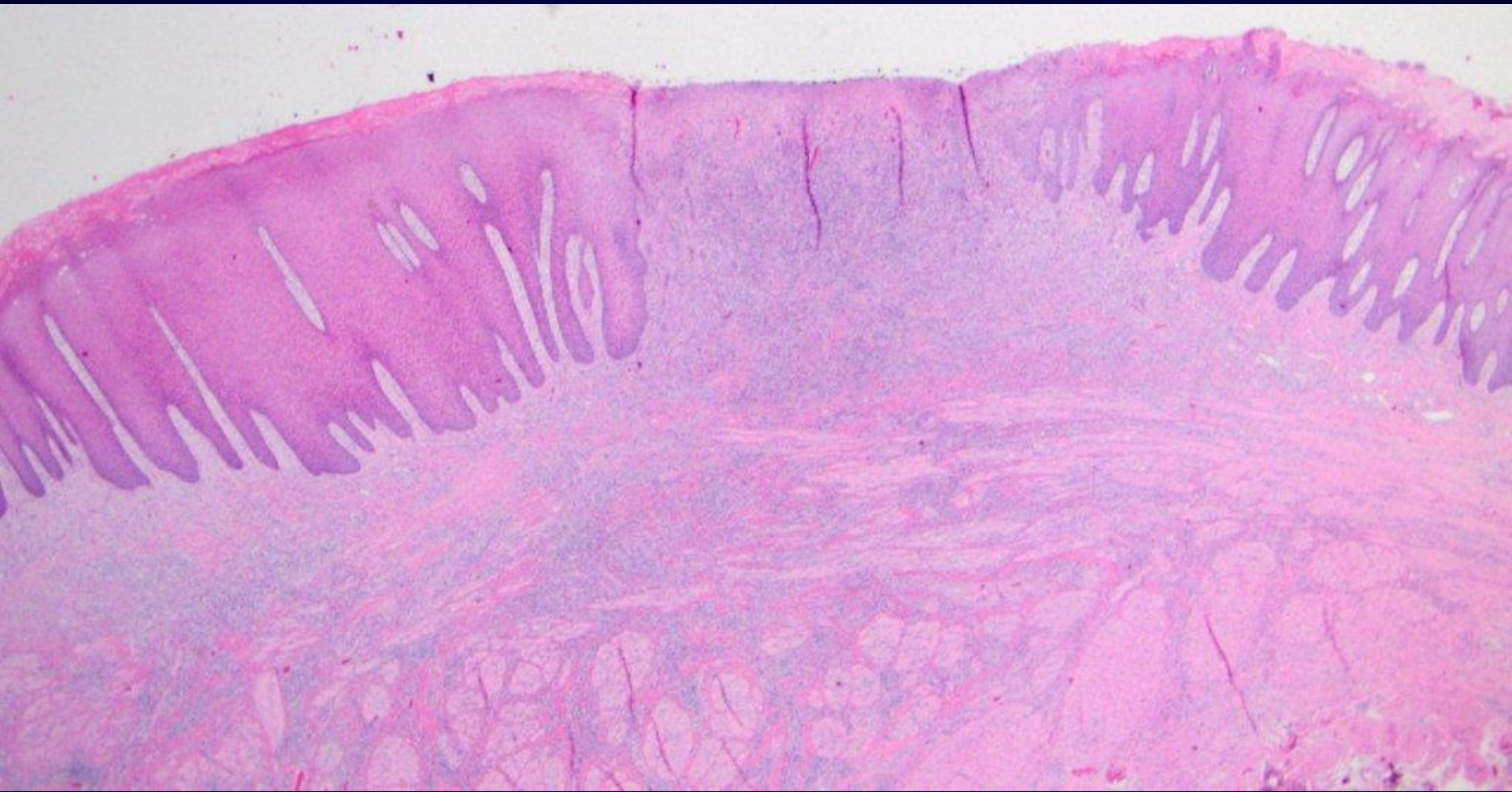




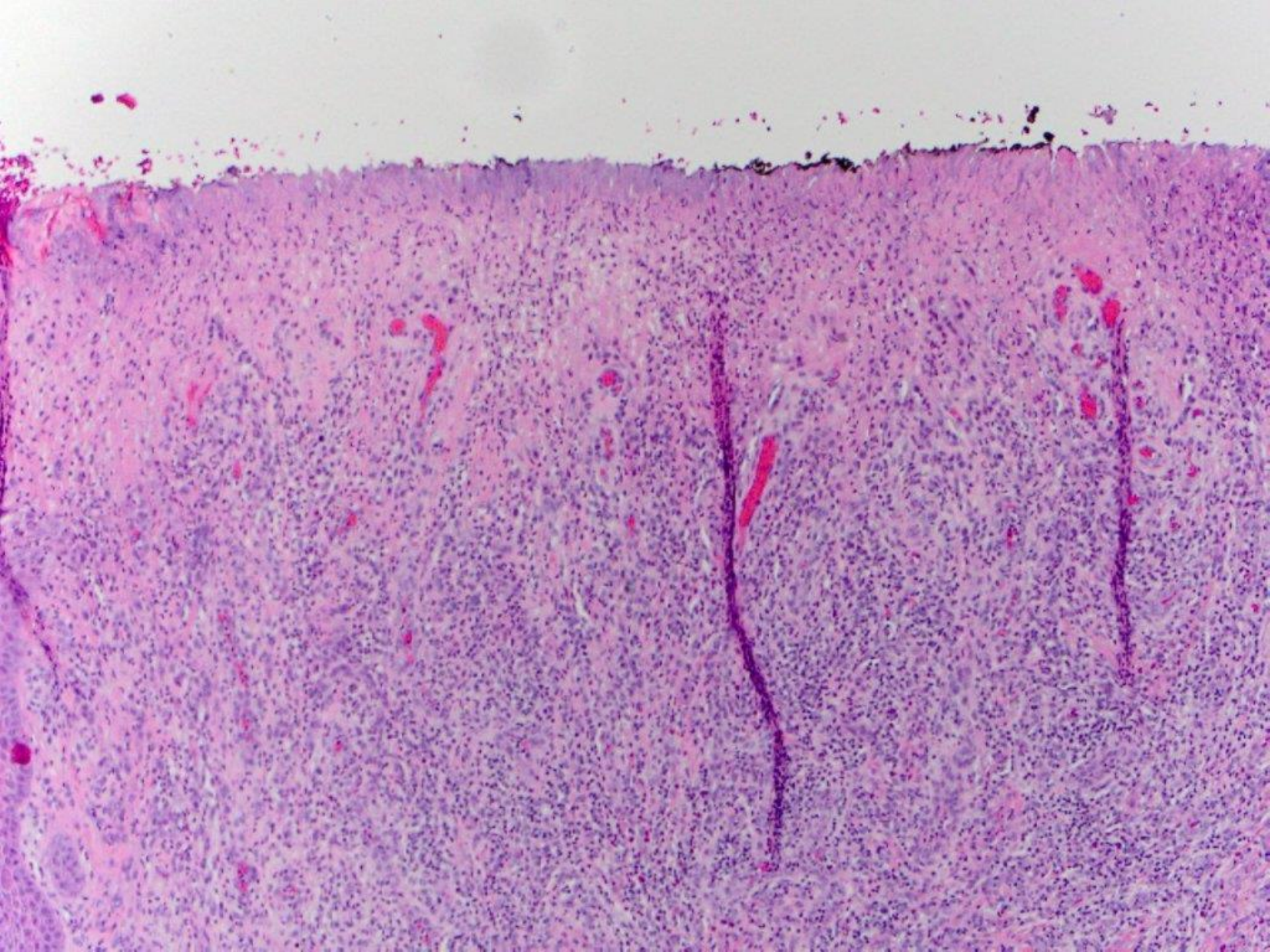


squamous cell carcinoma

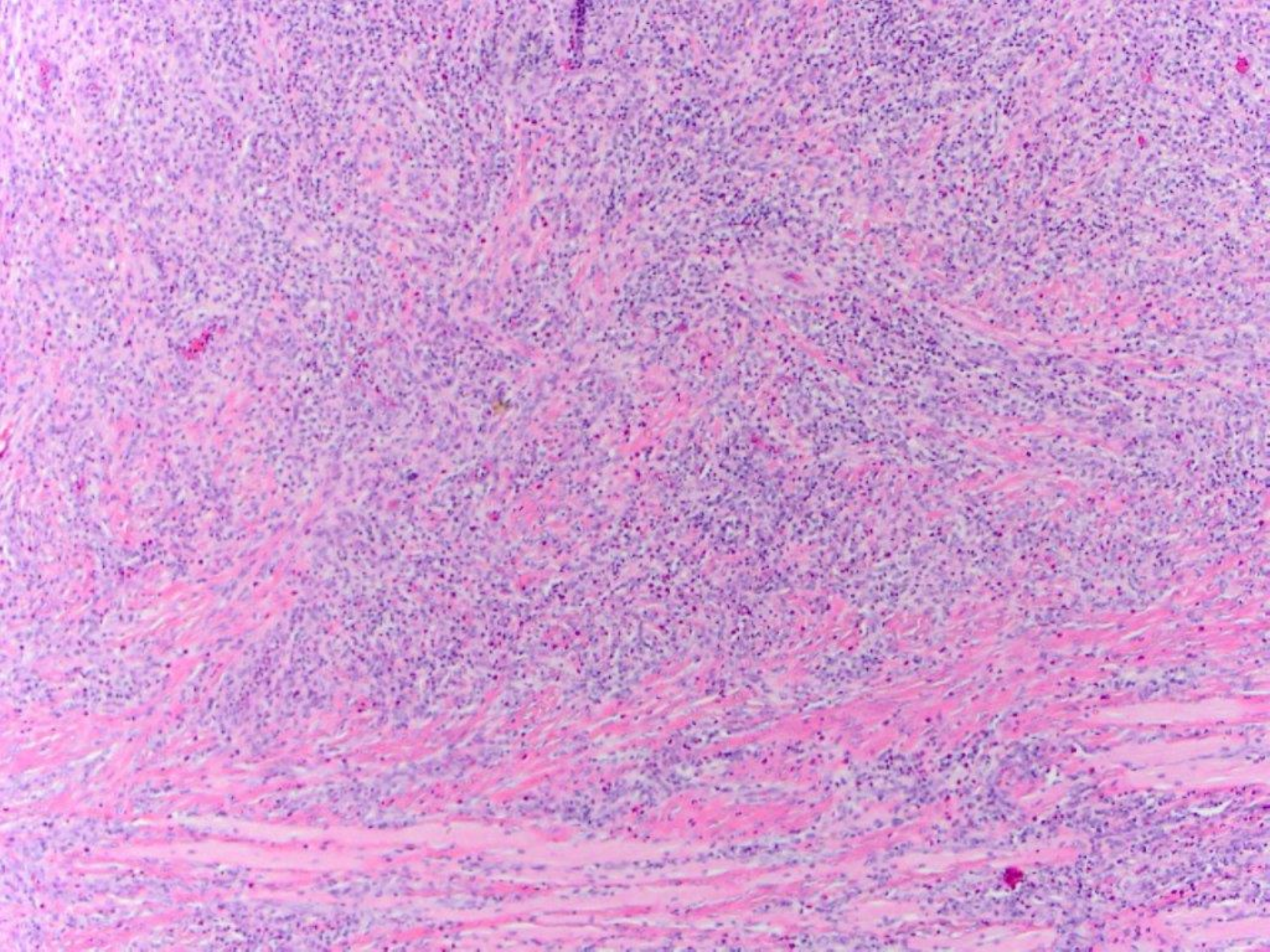




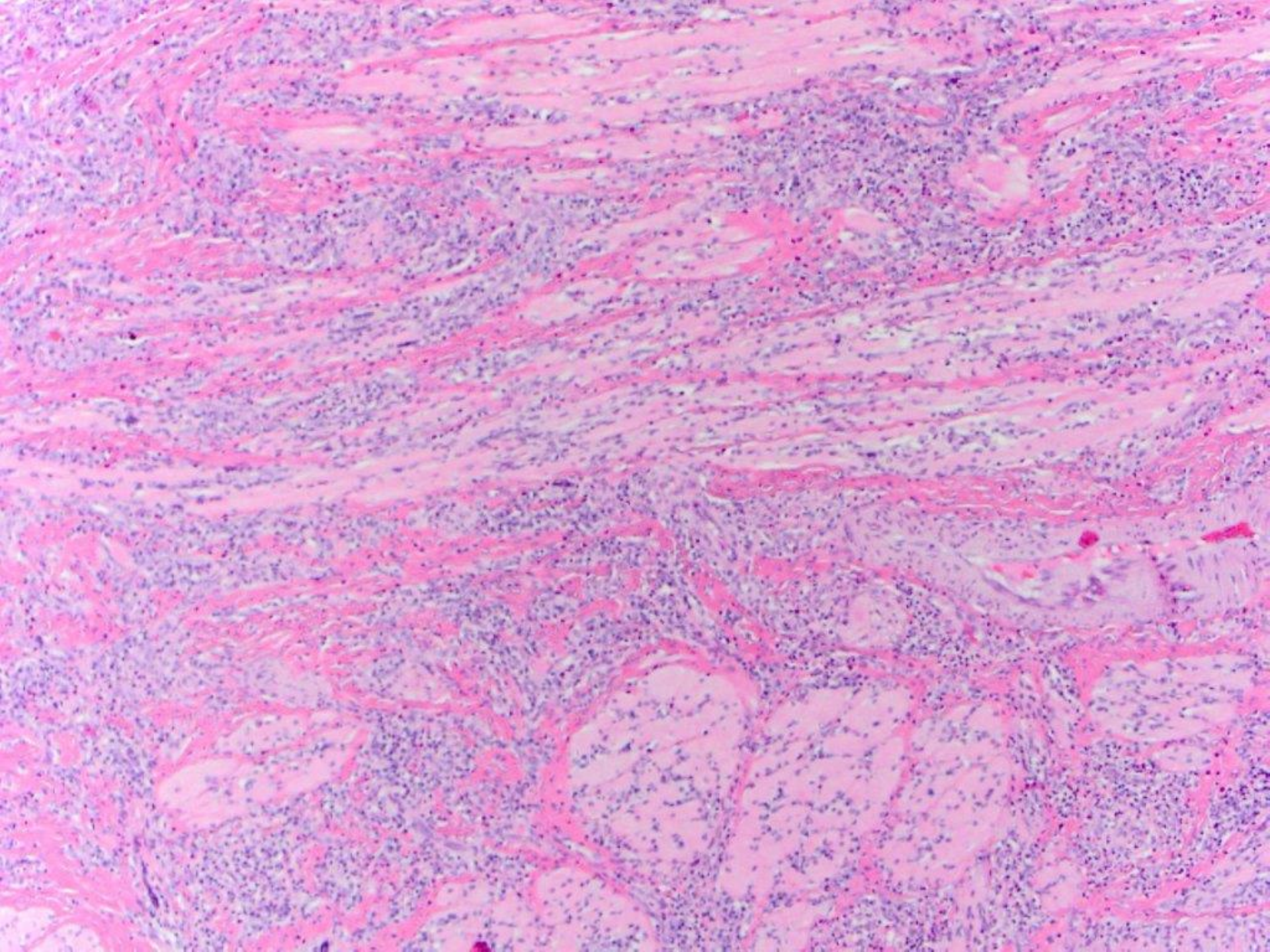




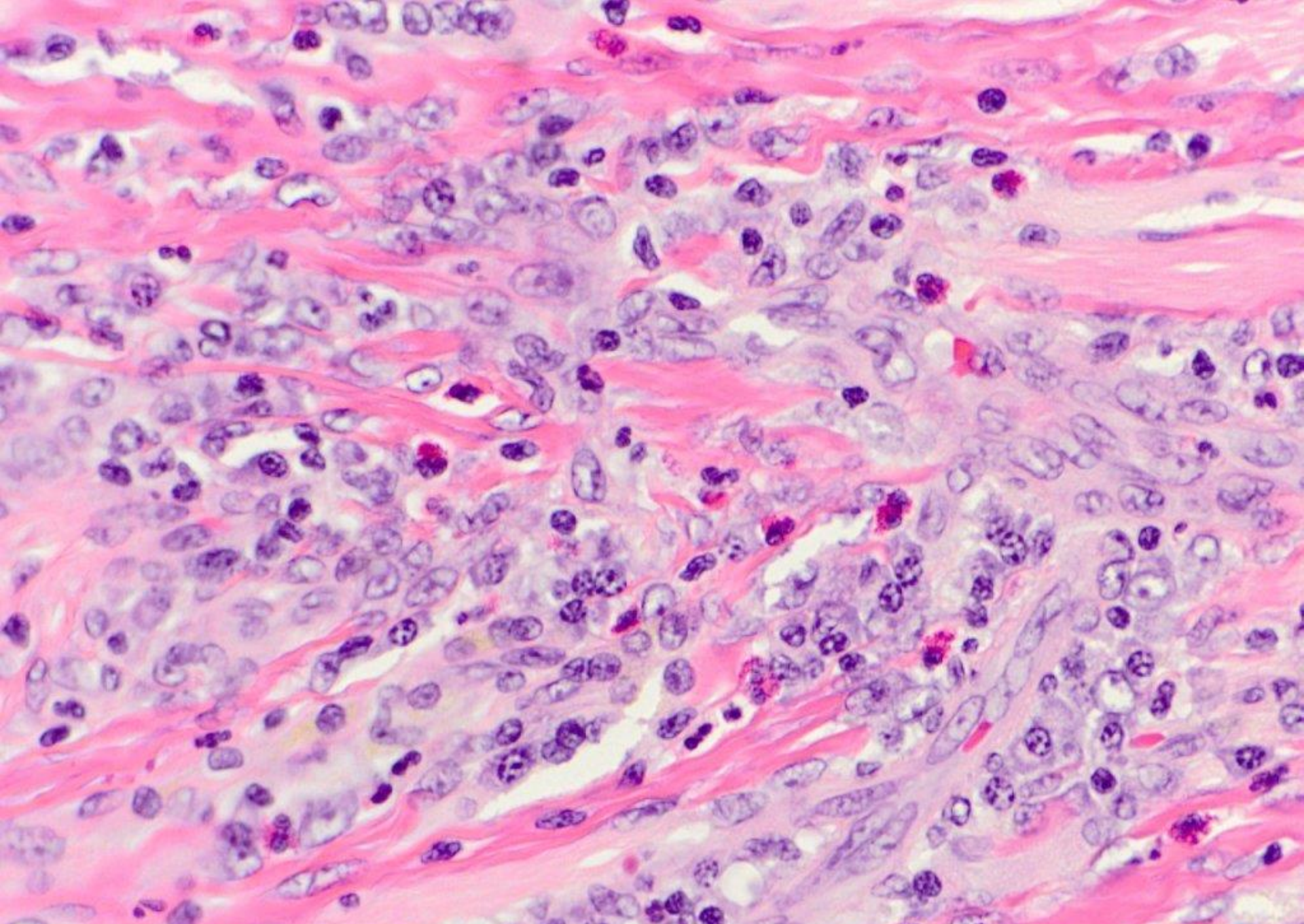






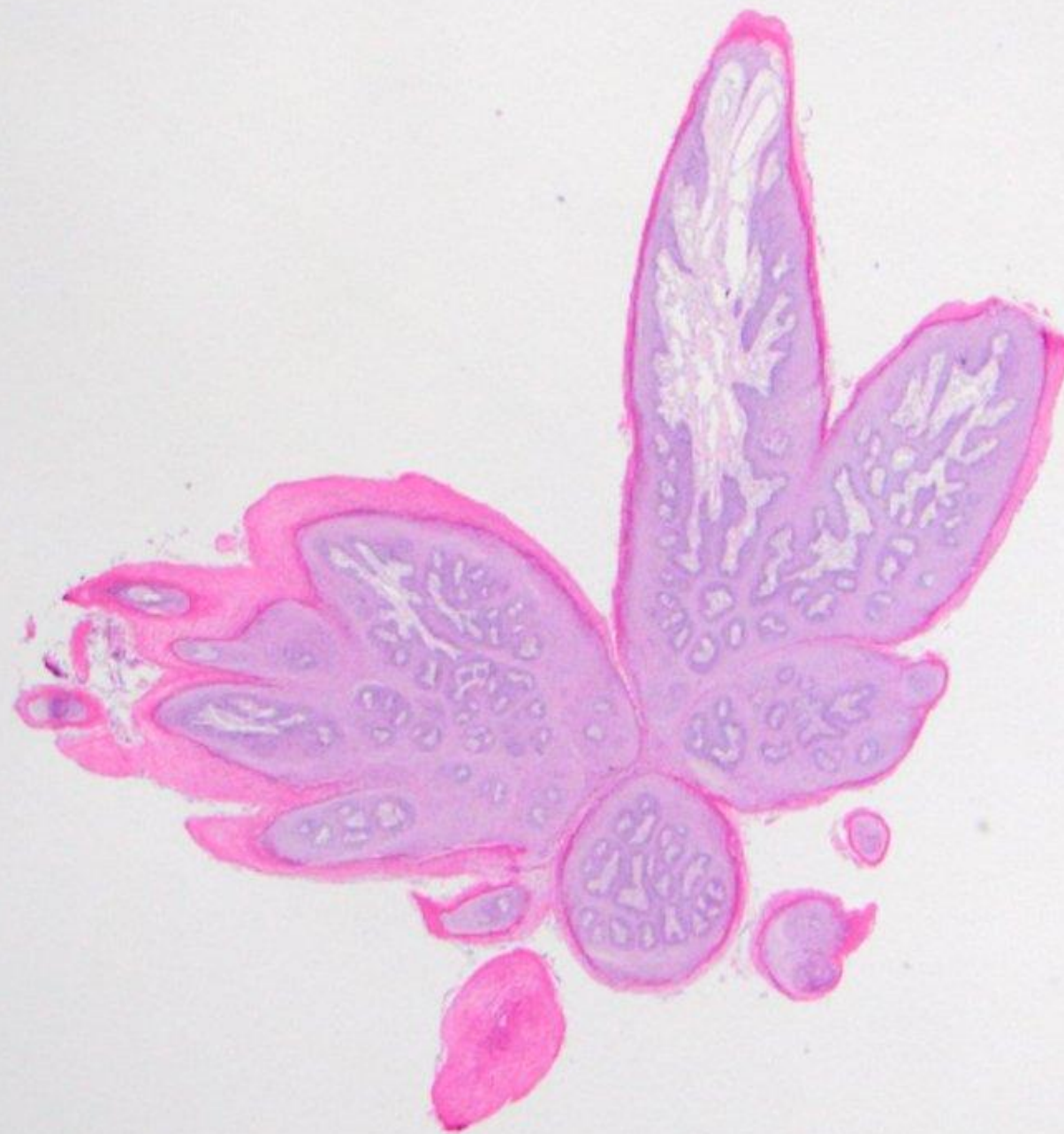





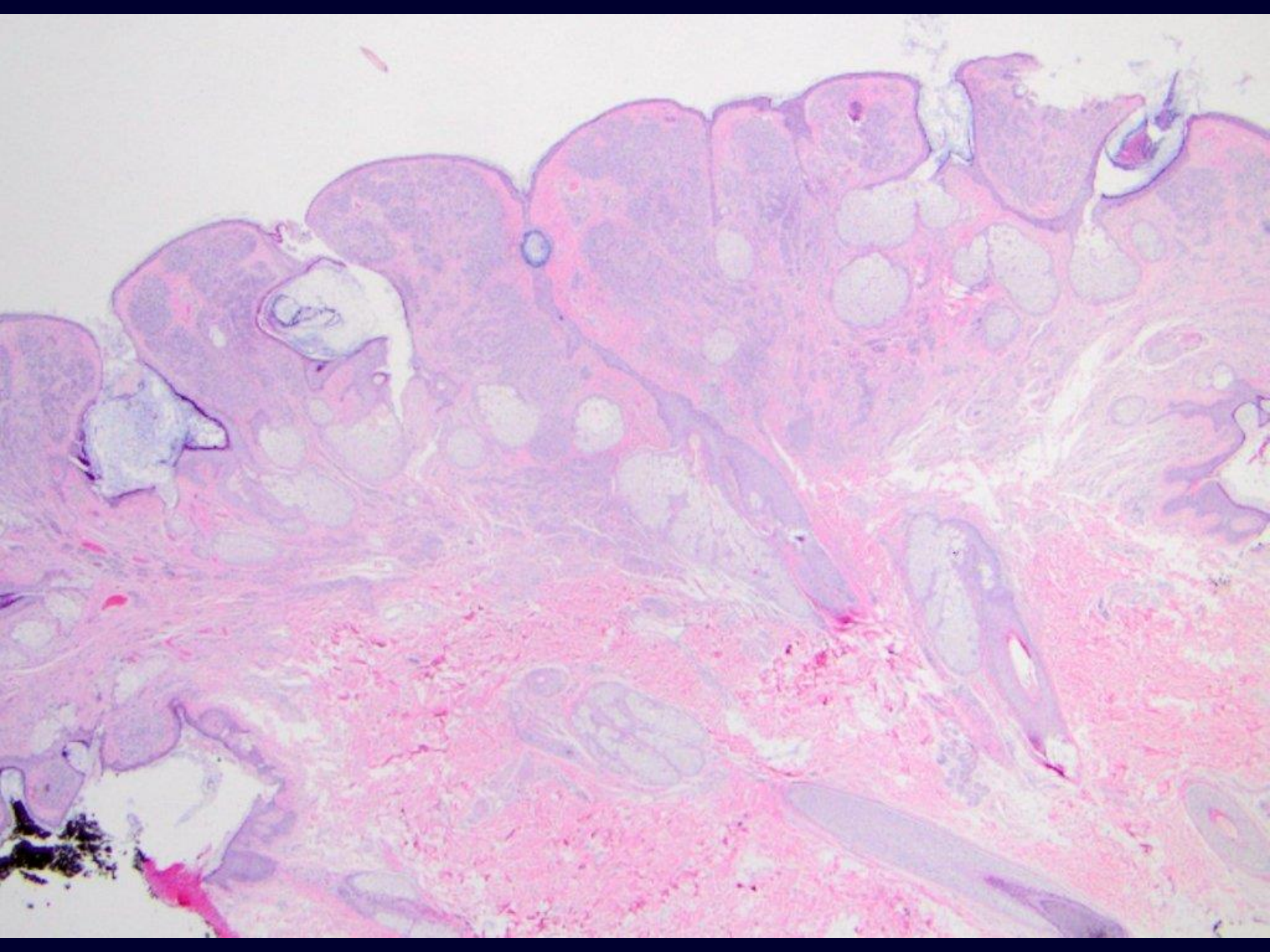
nonspecific ulcer with stromal eosinophilia ('TUGSE')



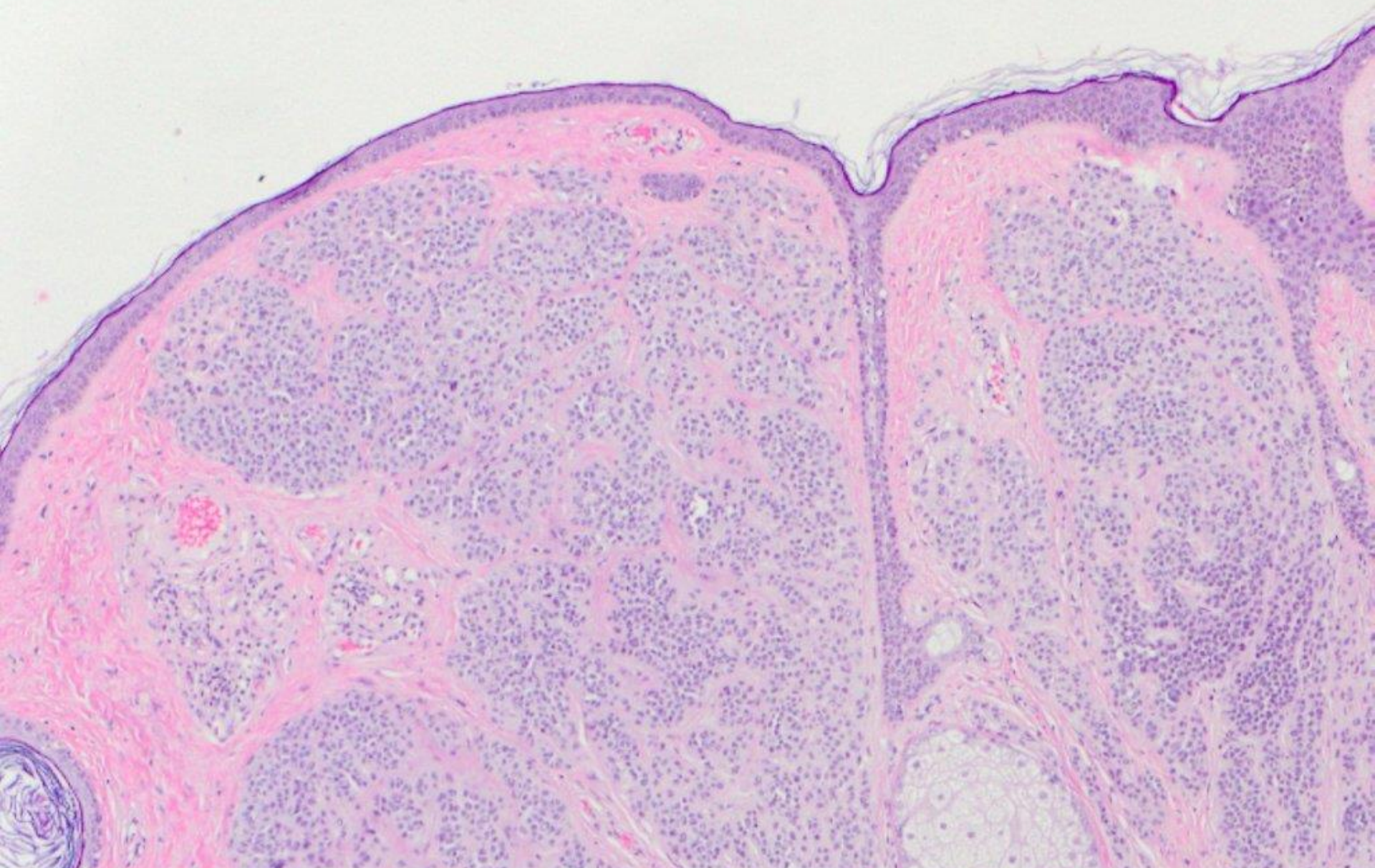


squamous papilloma



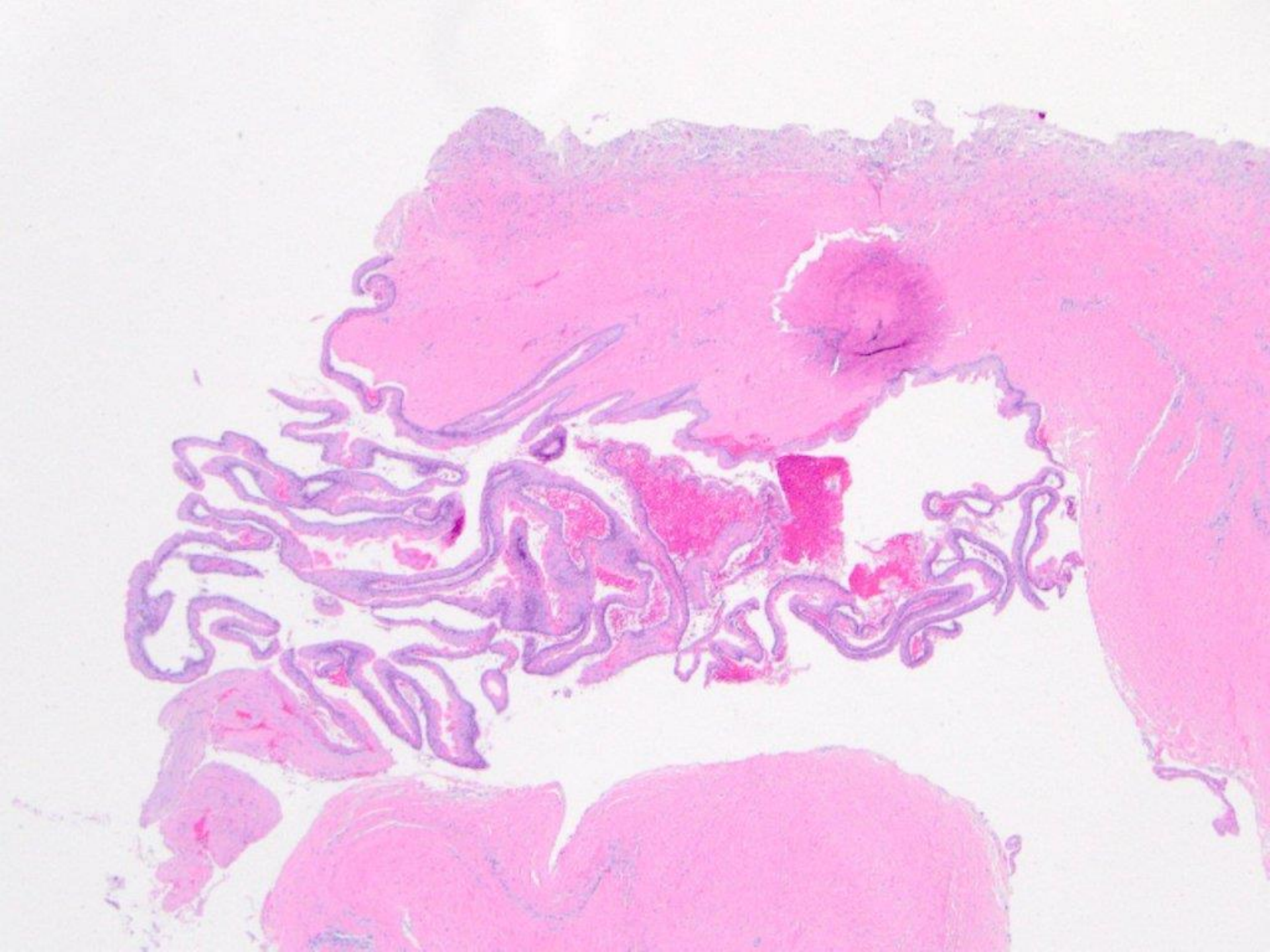




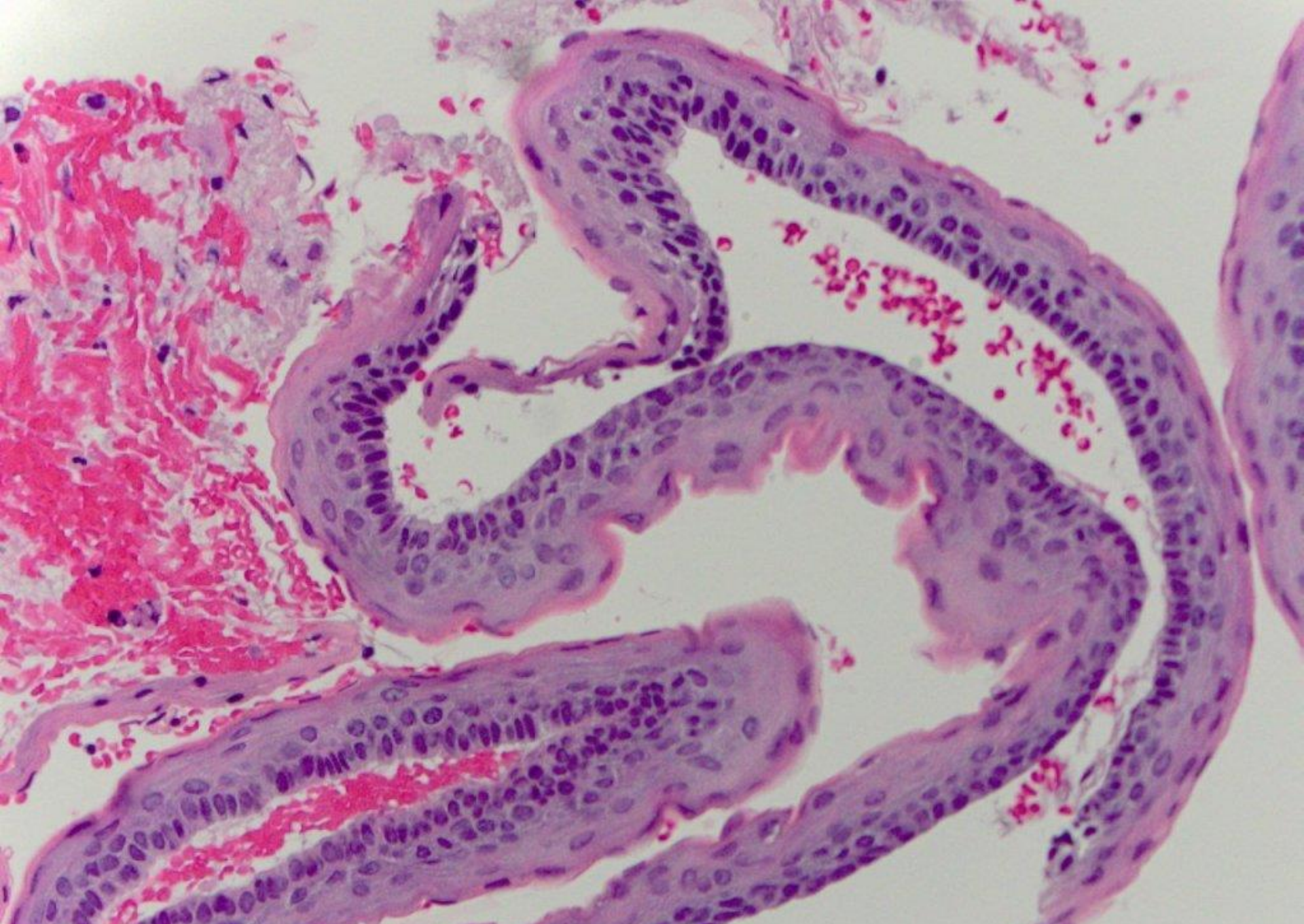


melanocytic nevus (skin)



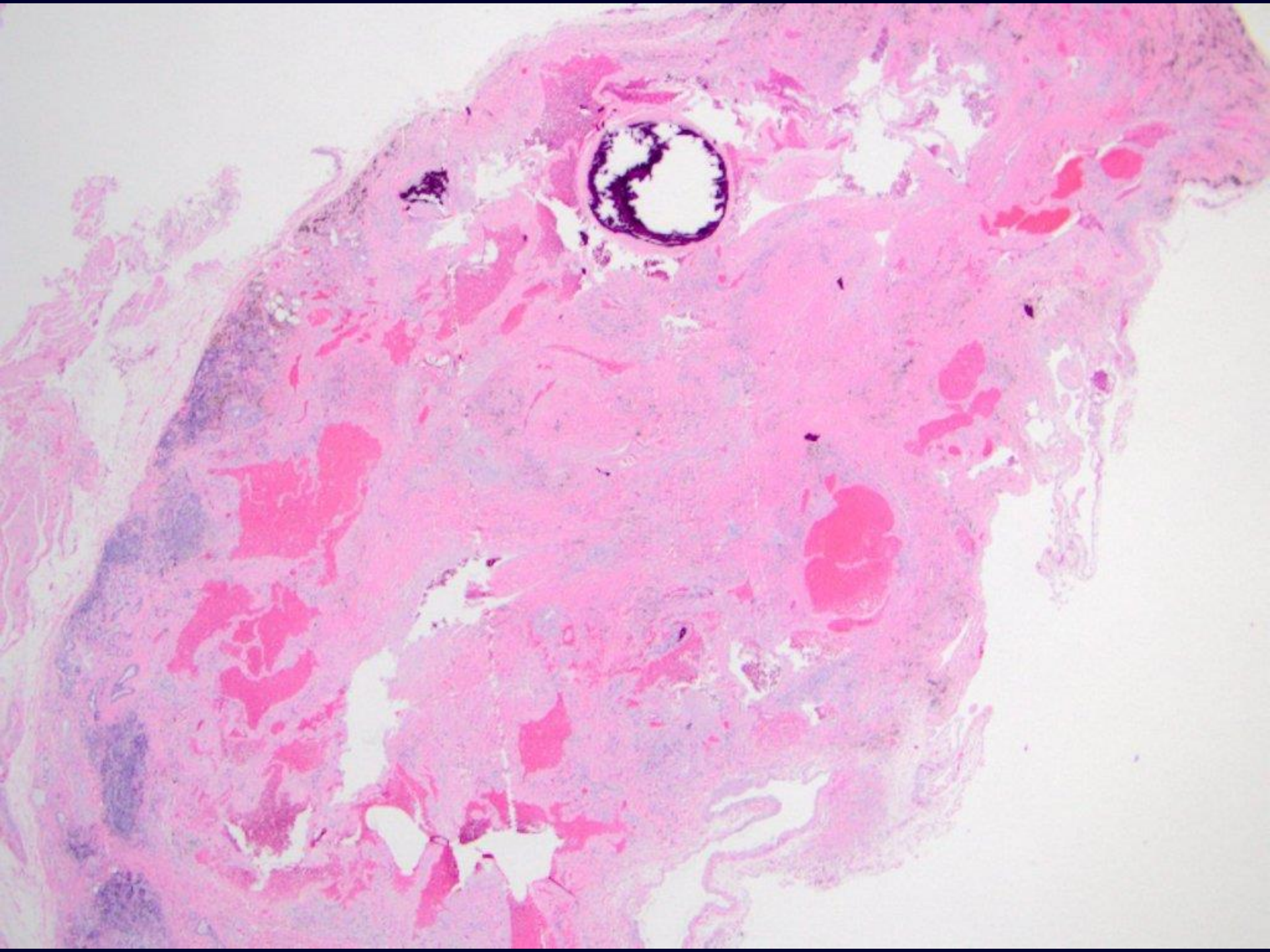




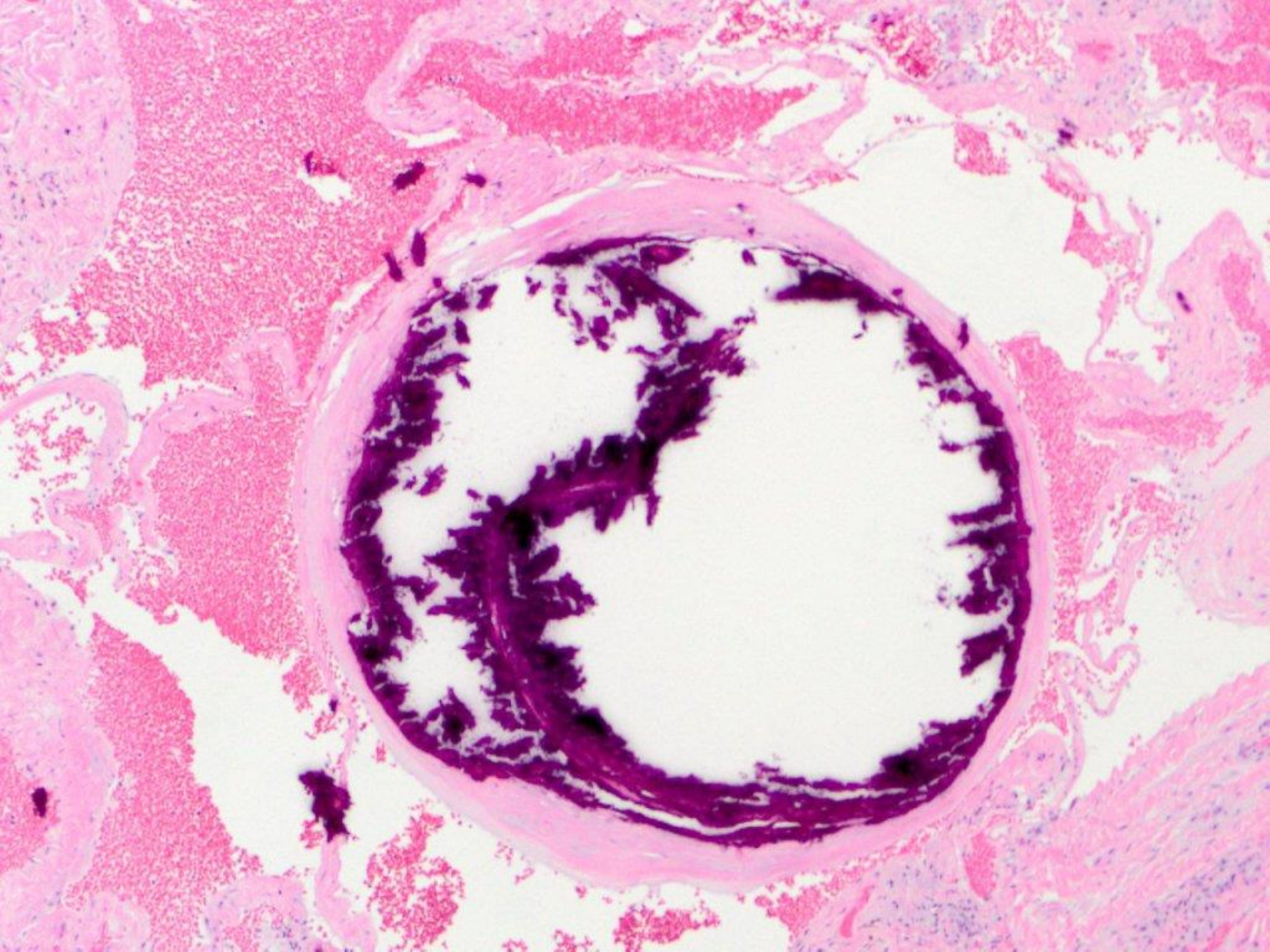


odontogenic keratocyst (keratocystic odontogenic tumor)

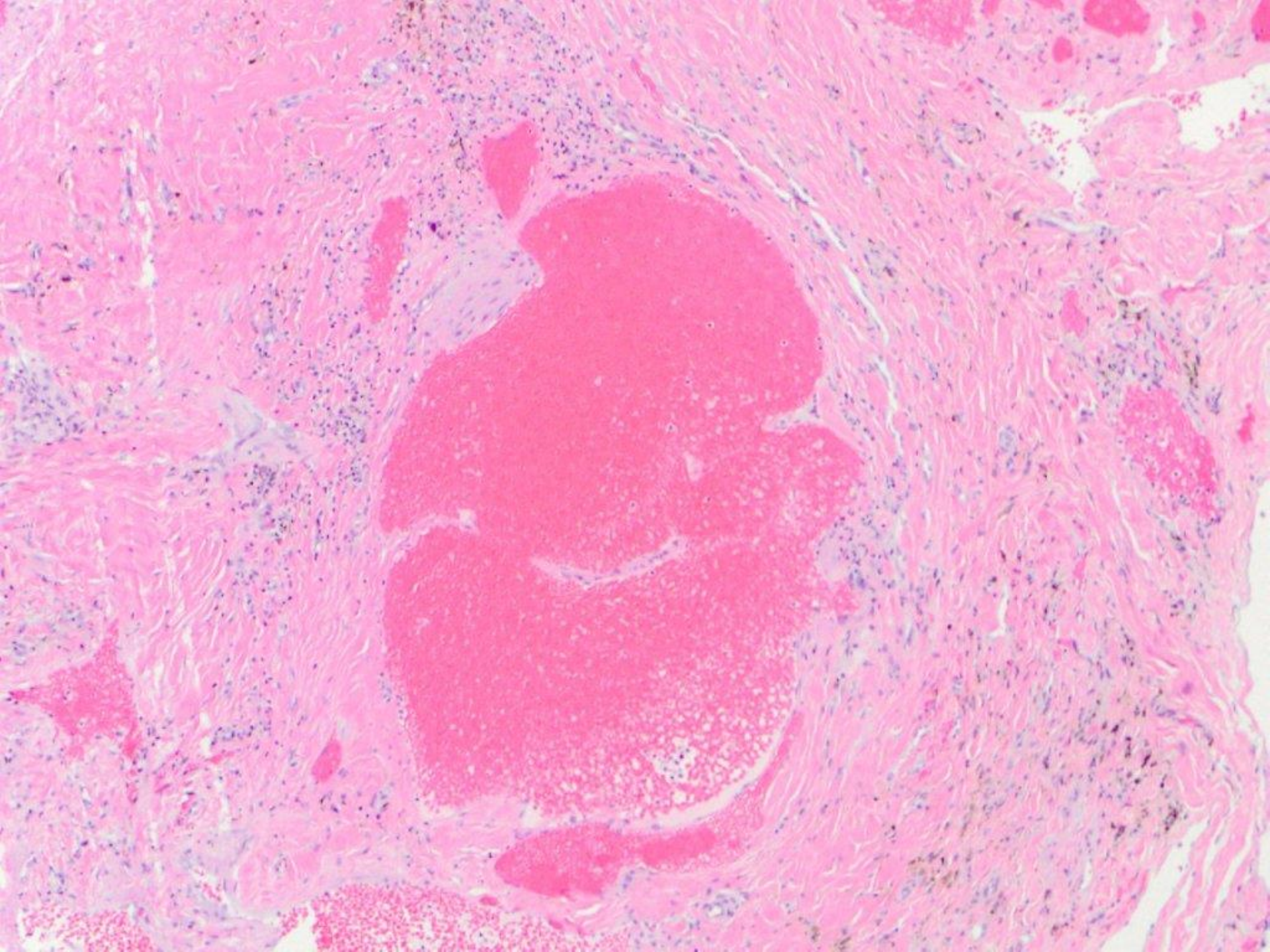




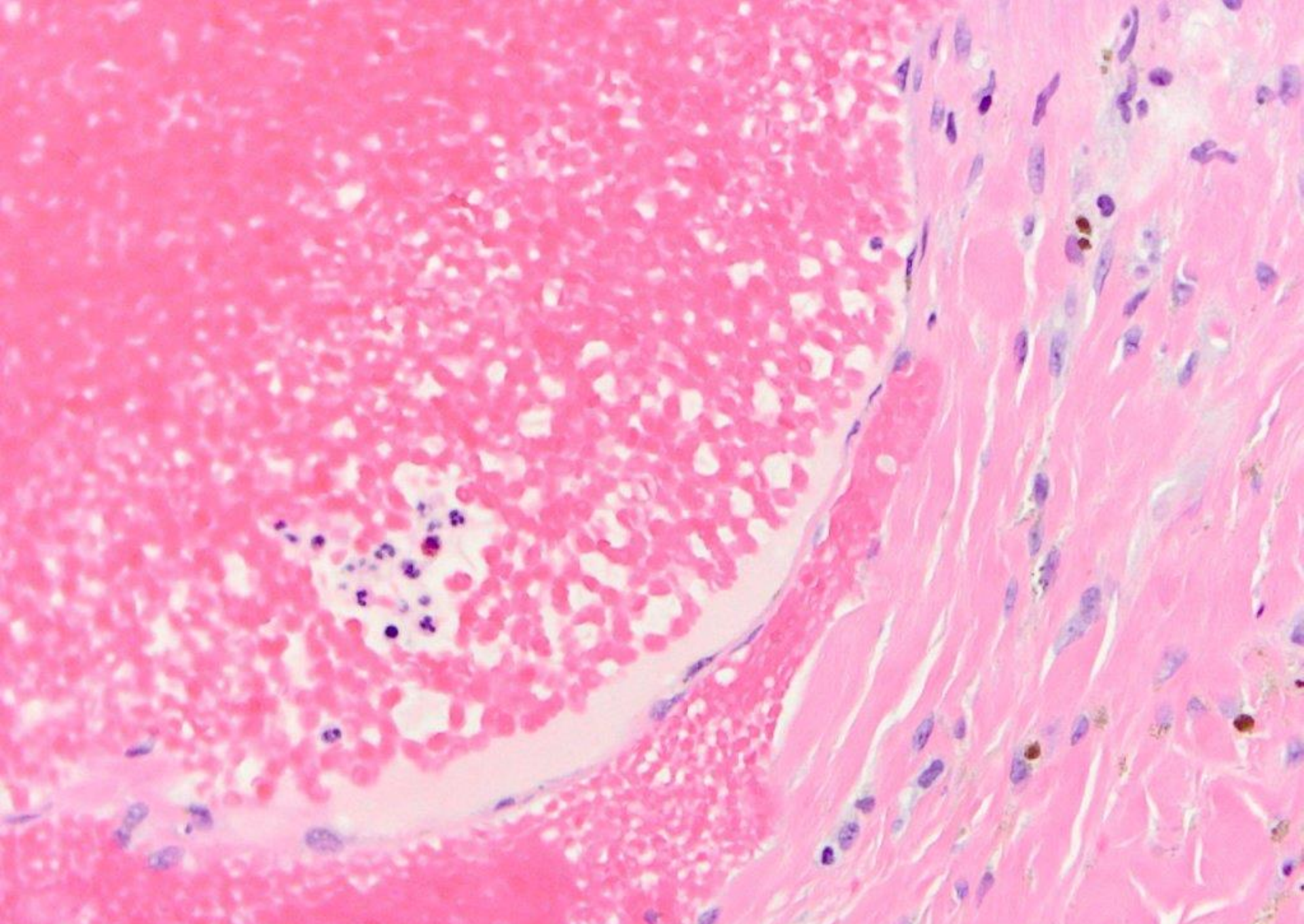






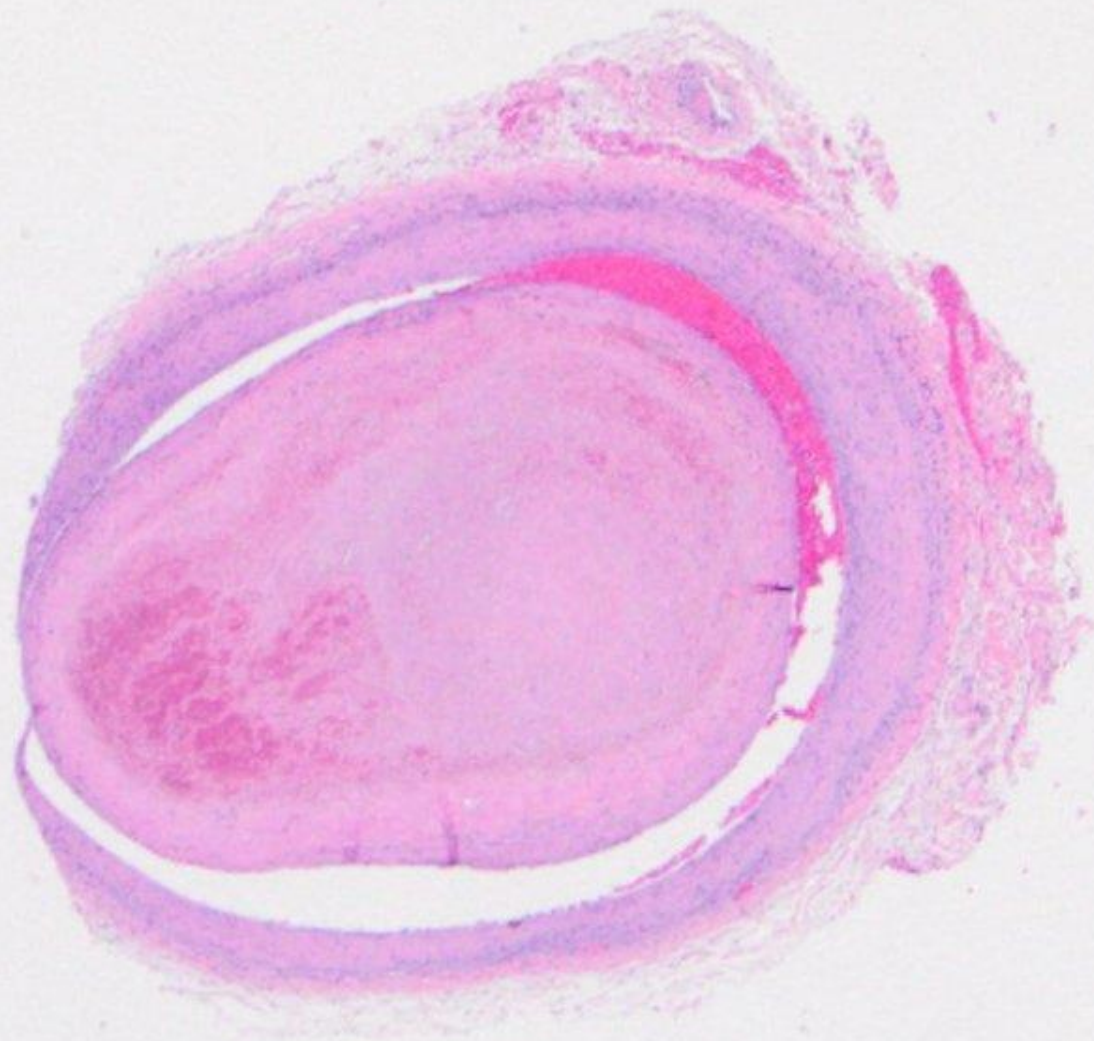




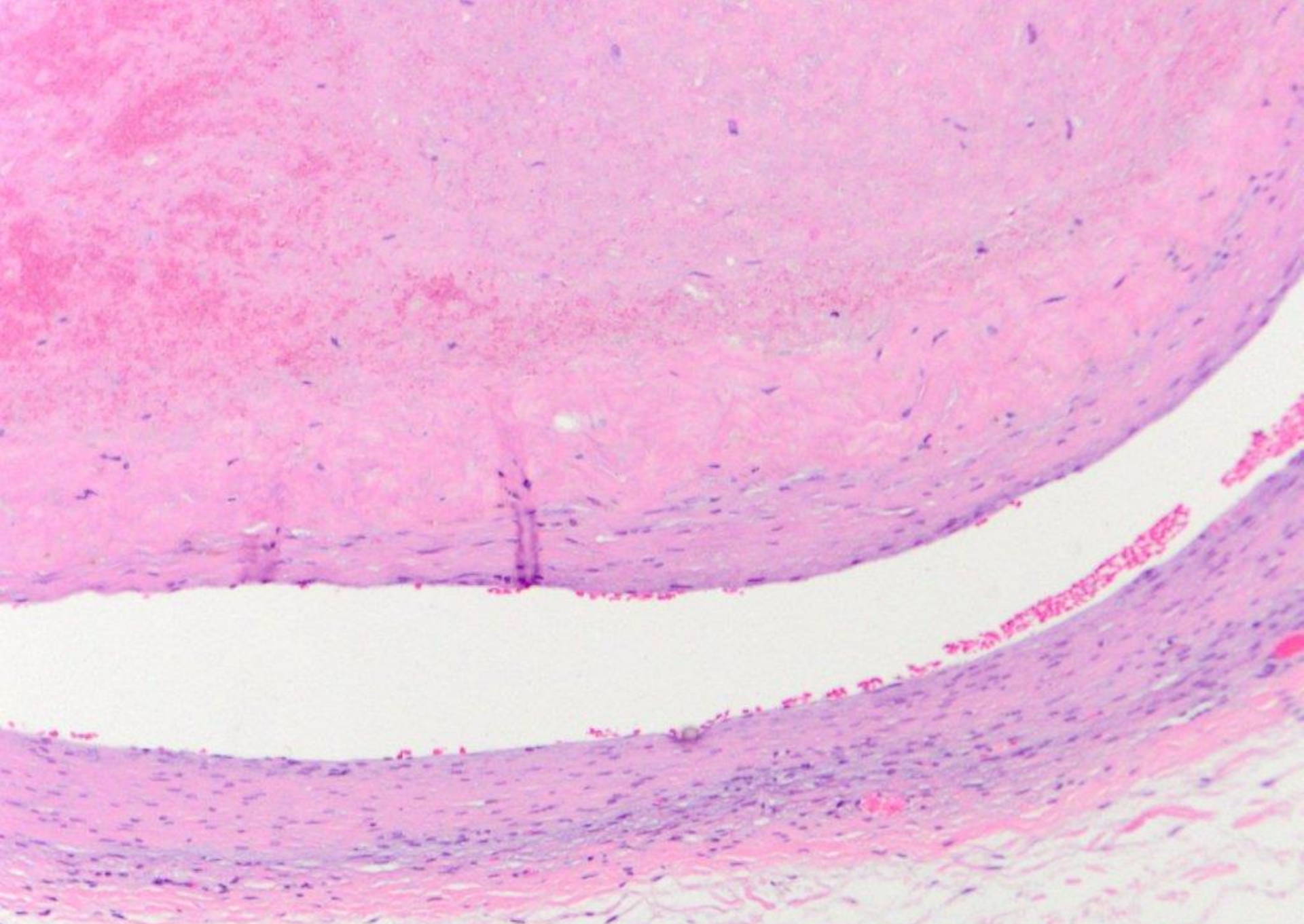


cavernous hemangioma with multiple thrombi



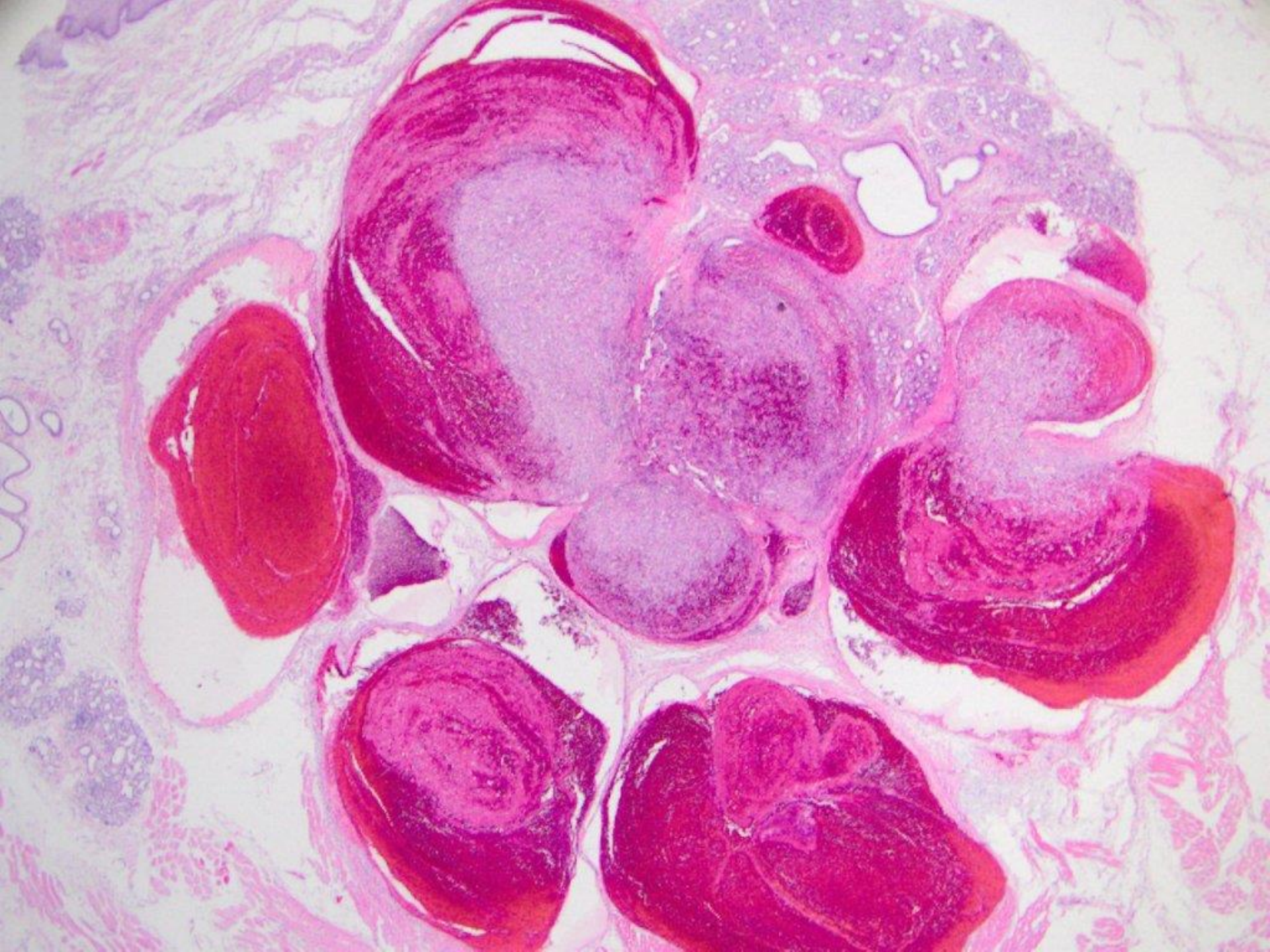




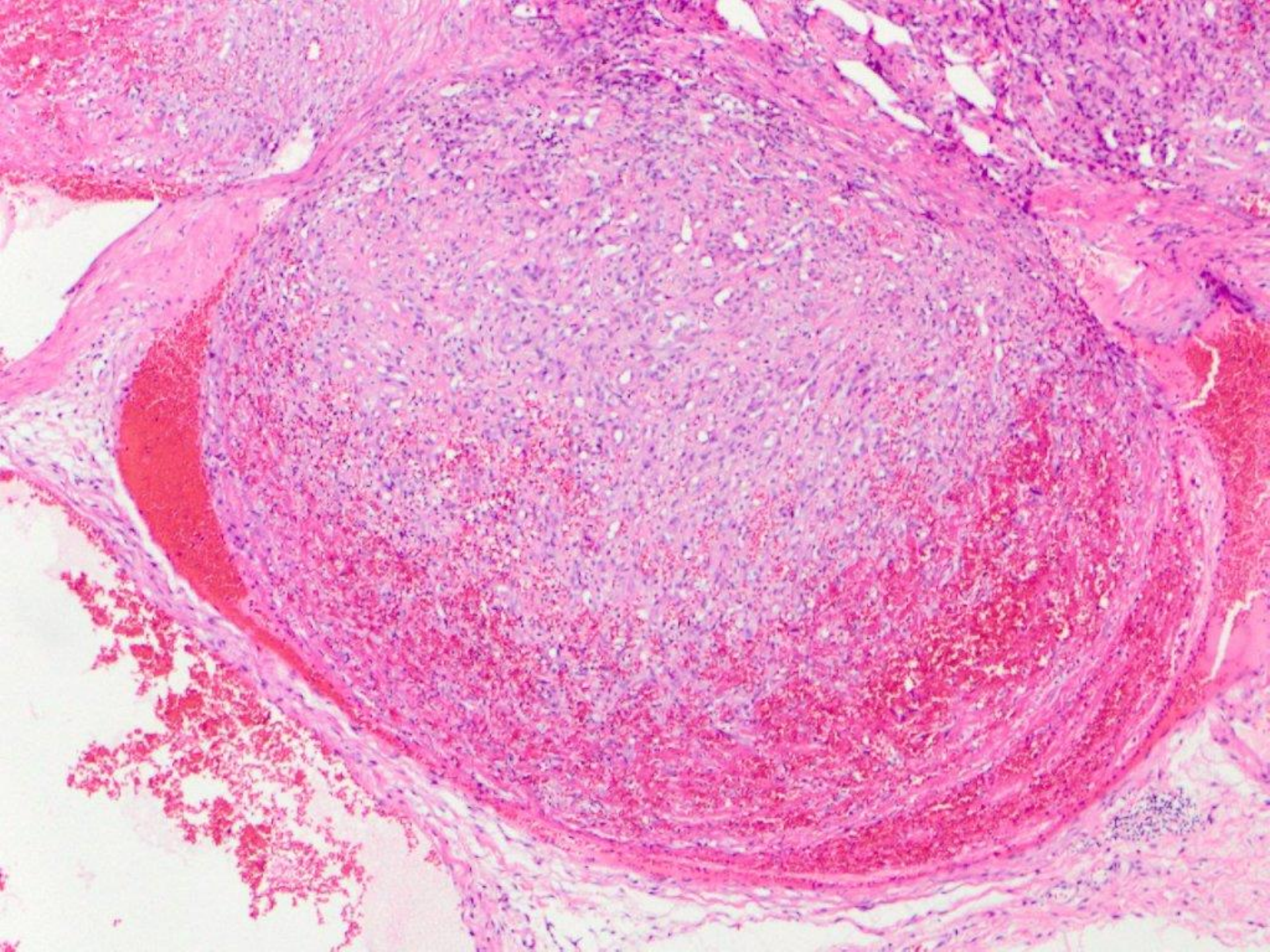


varix with organizing thrombus

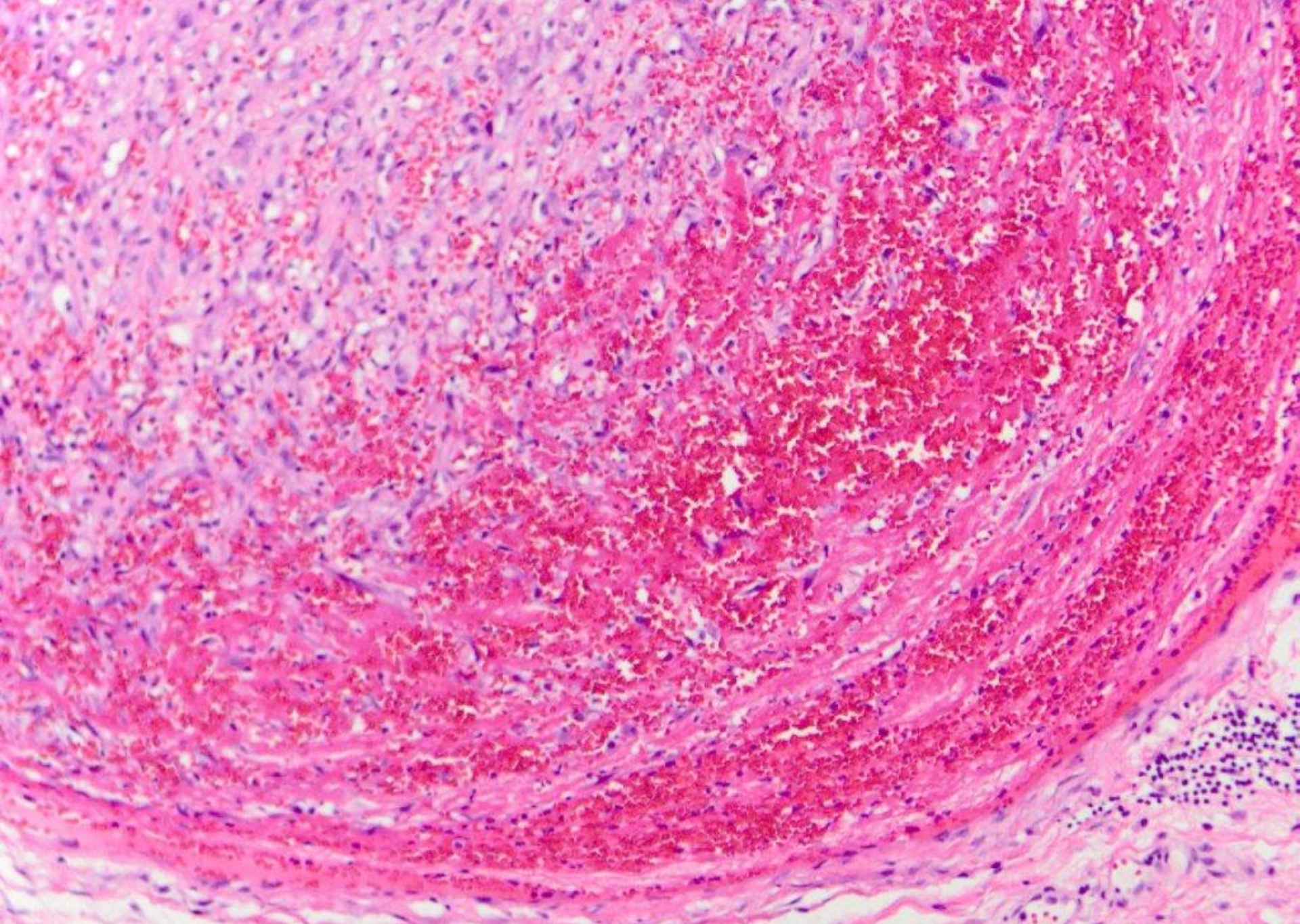






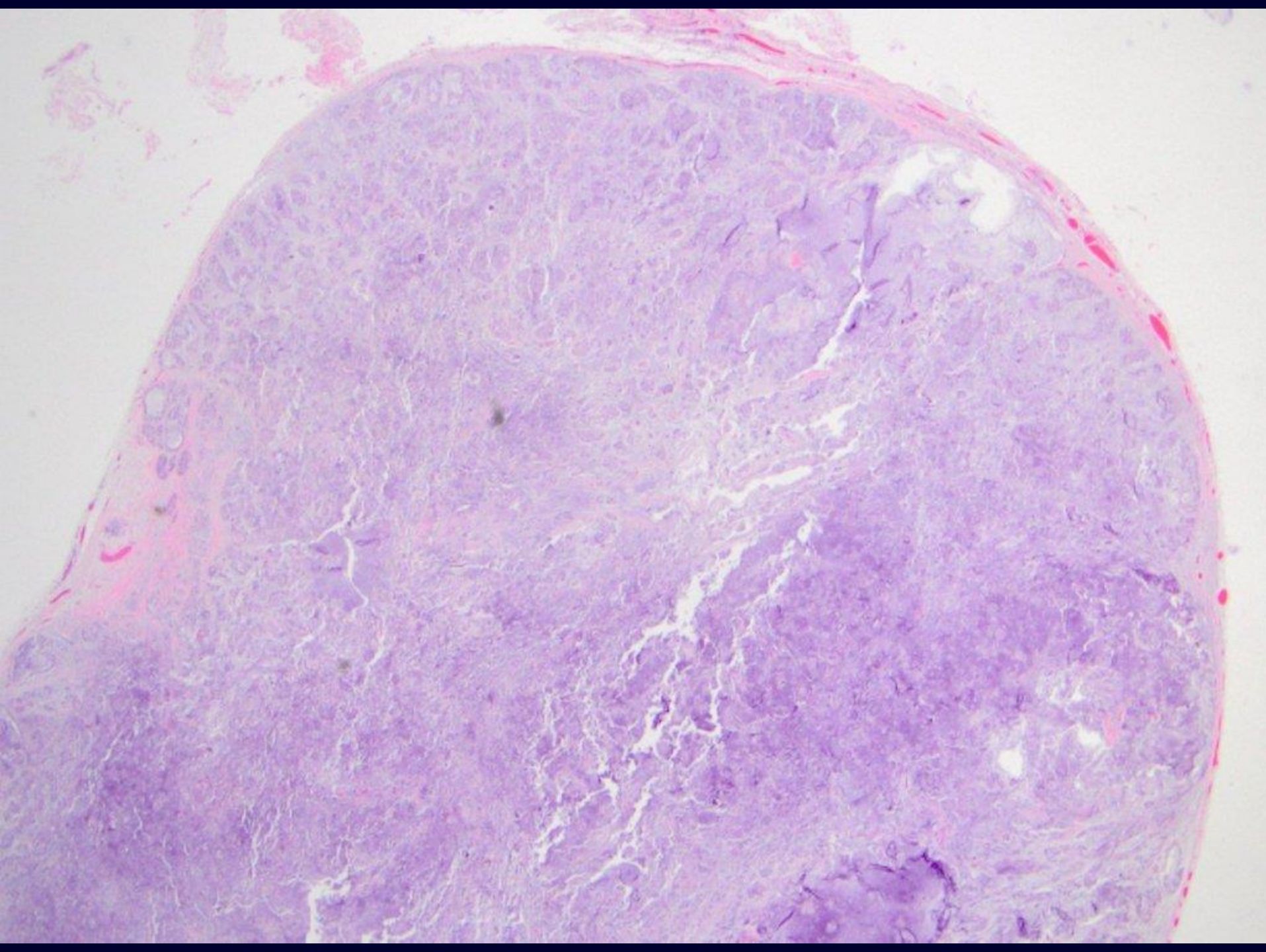




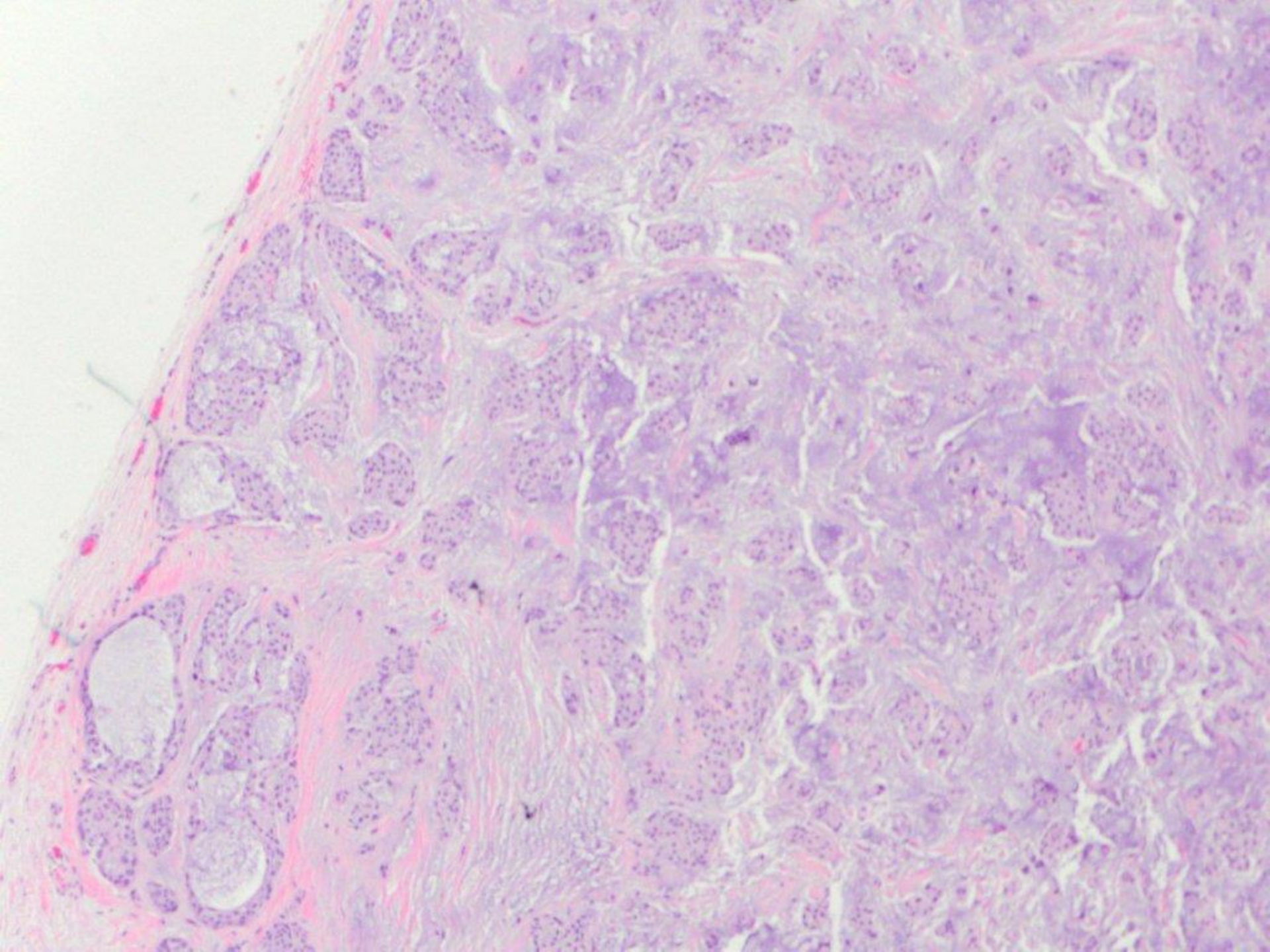


Cavernous hemangioma with multiple organizing thrombi, associated with minor salivary glands

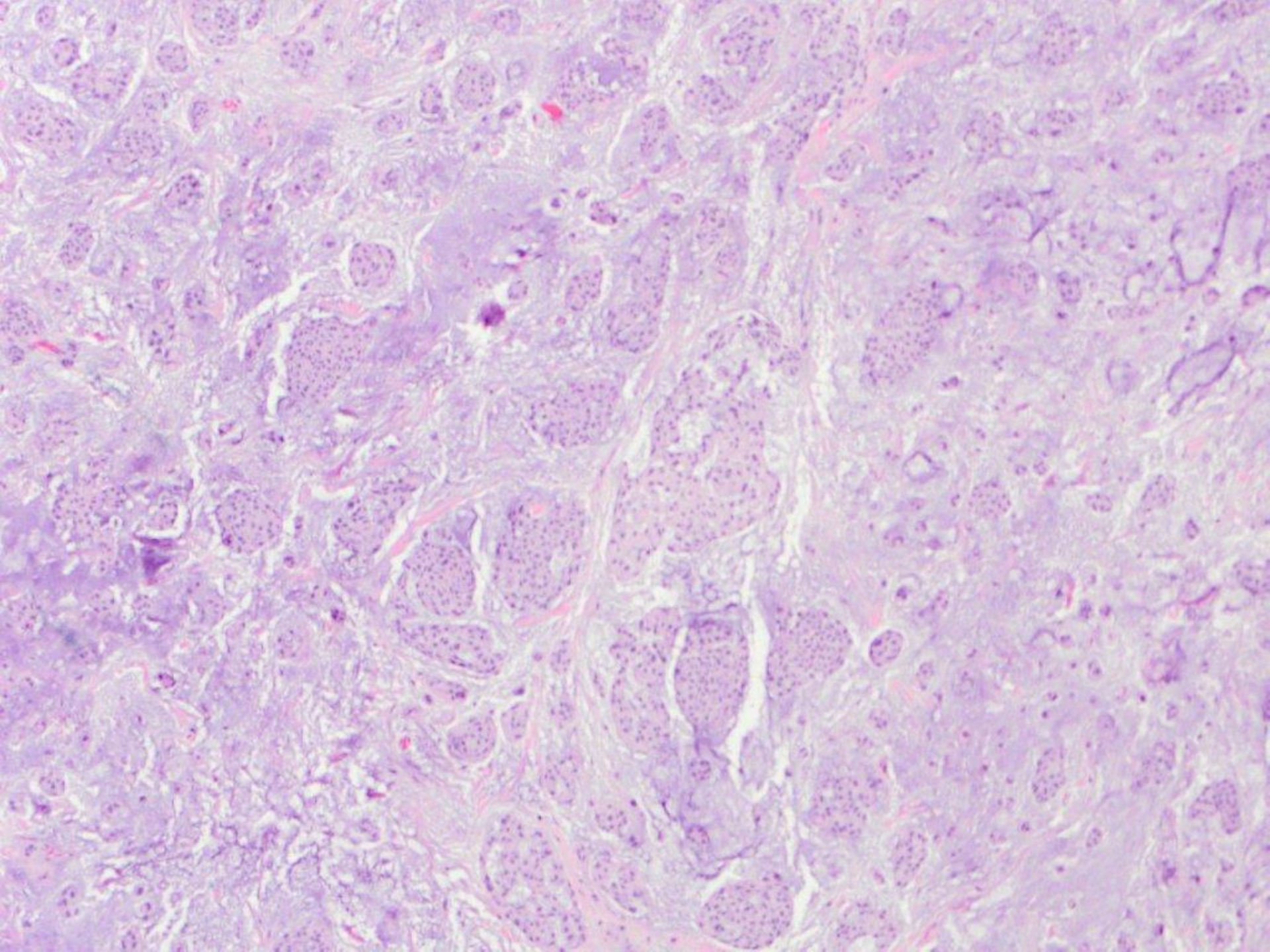




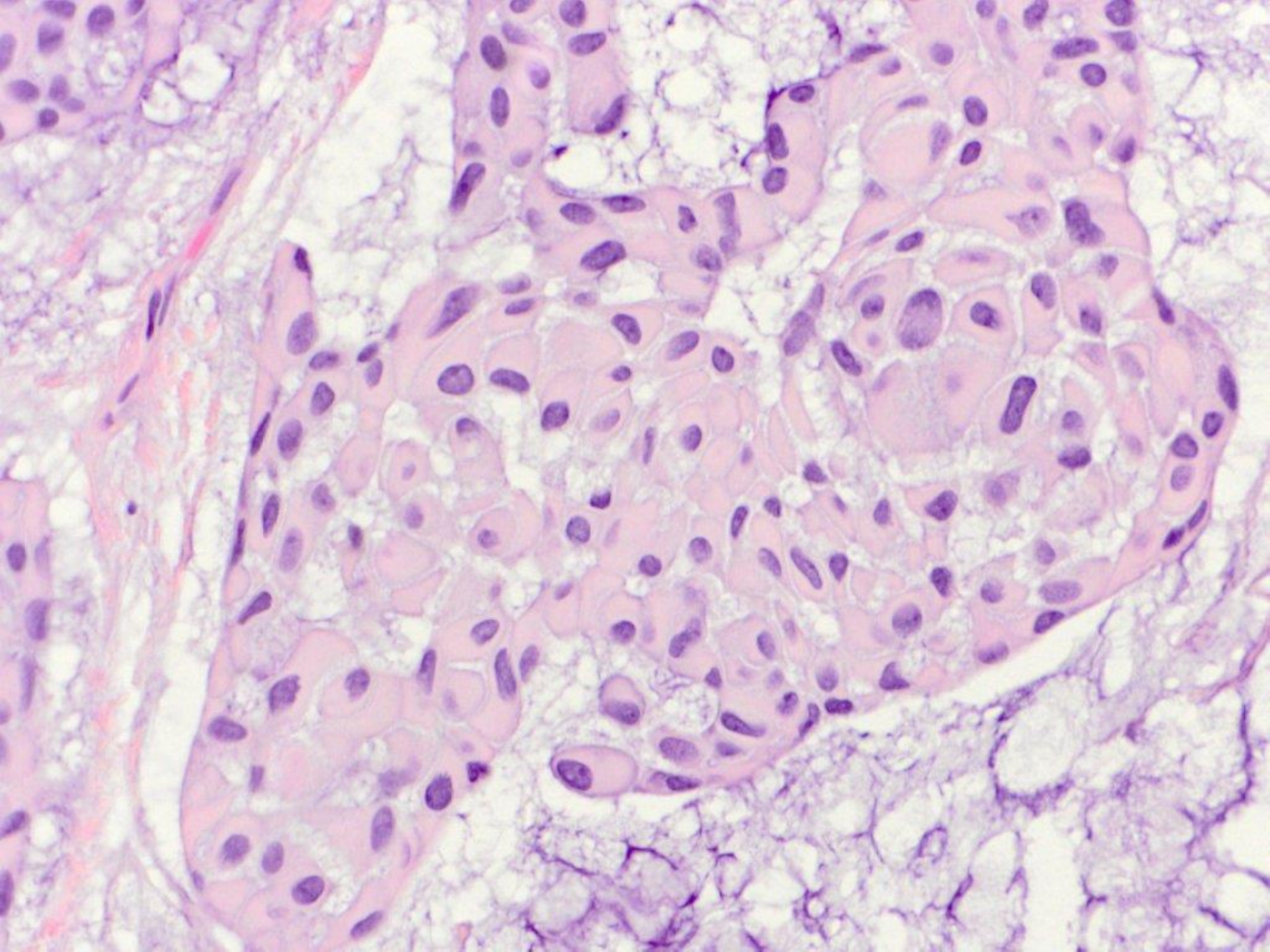




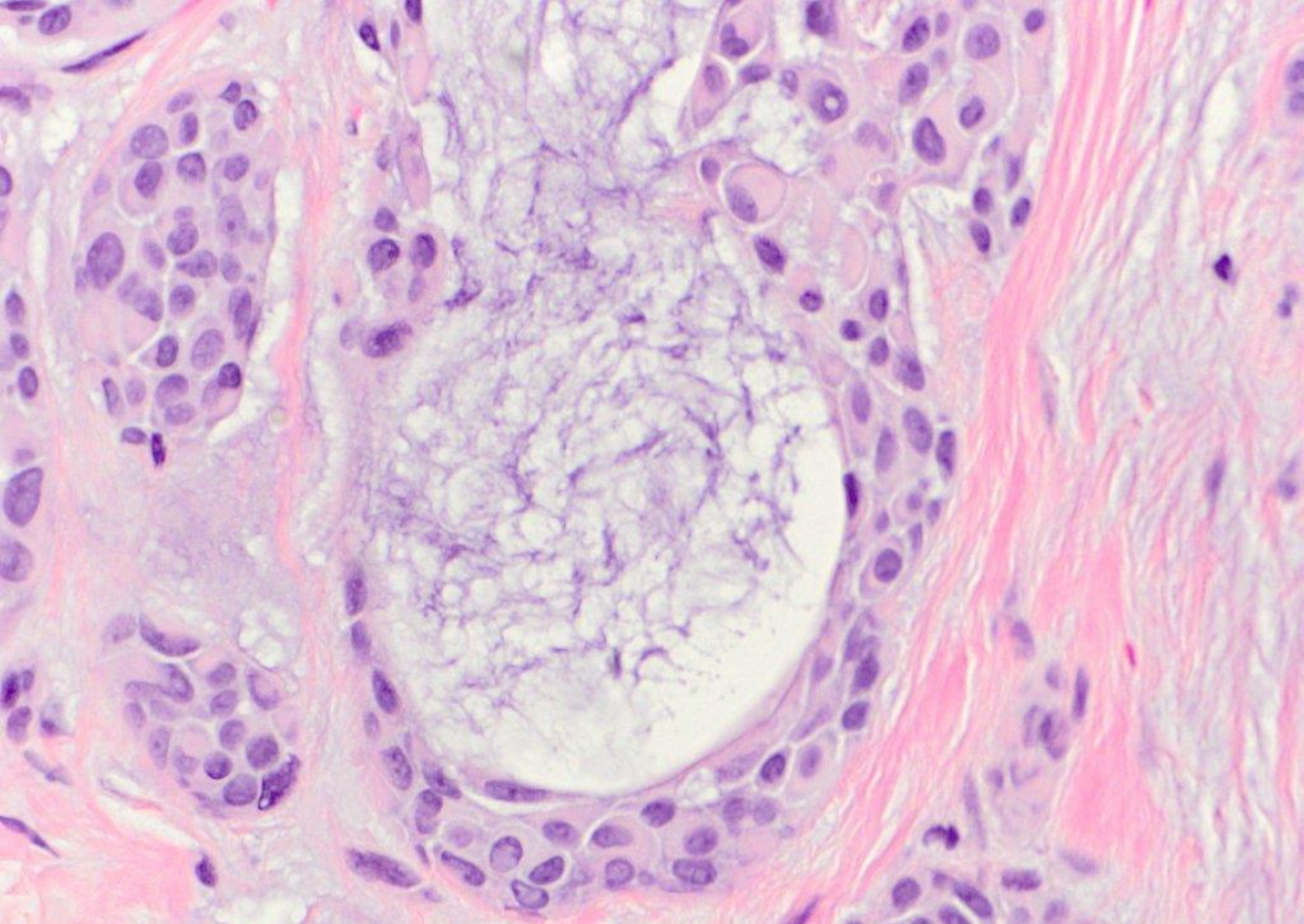






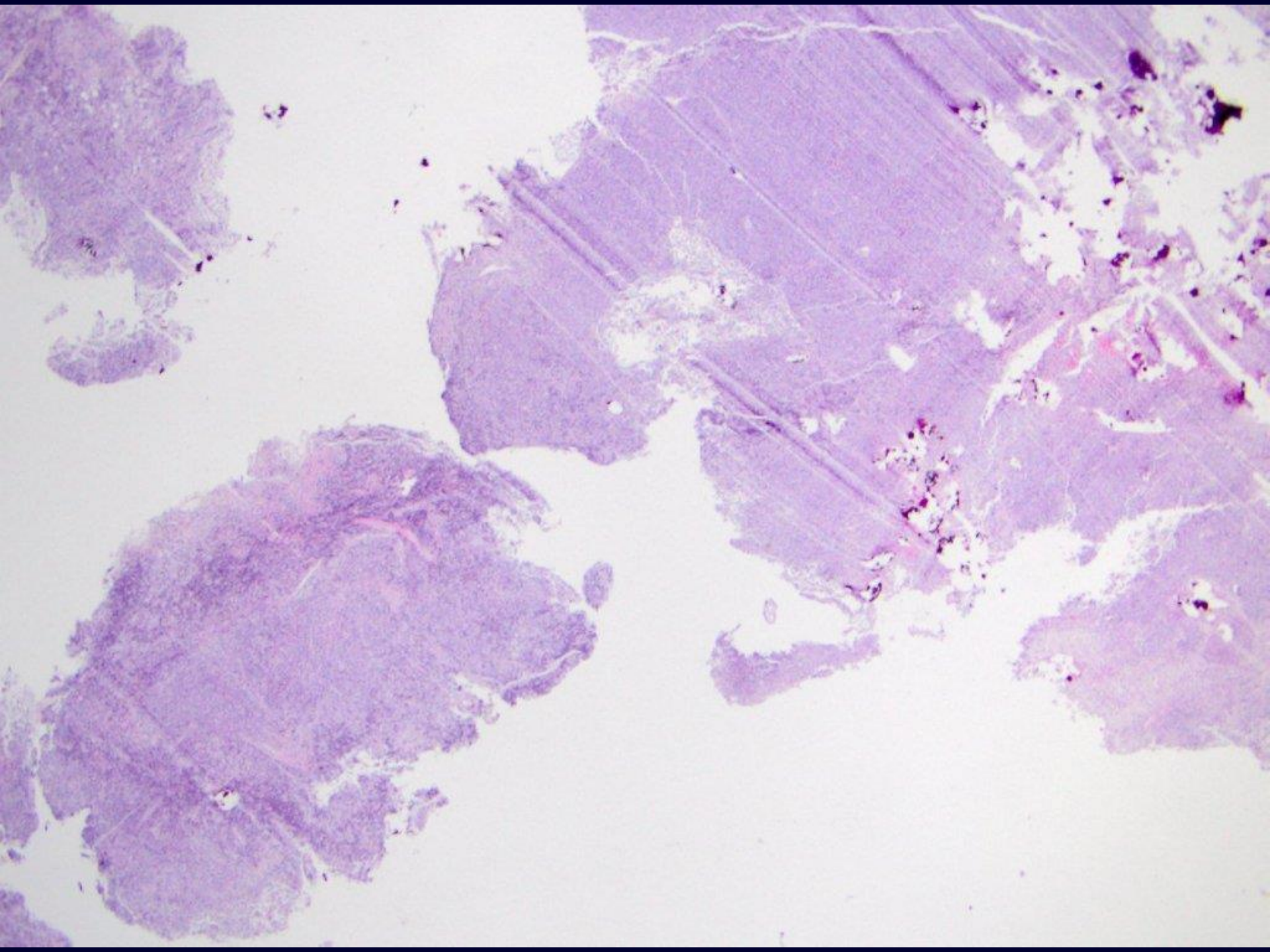




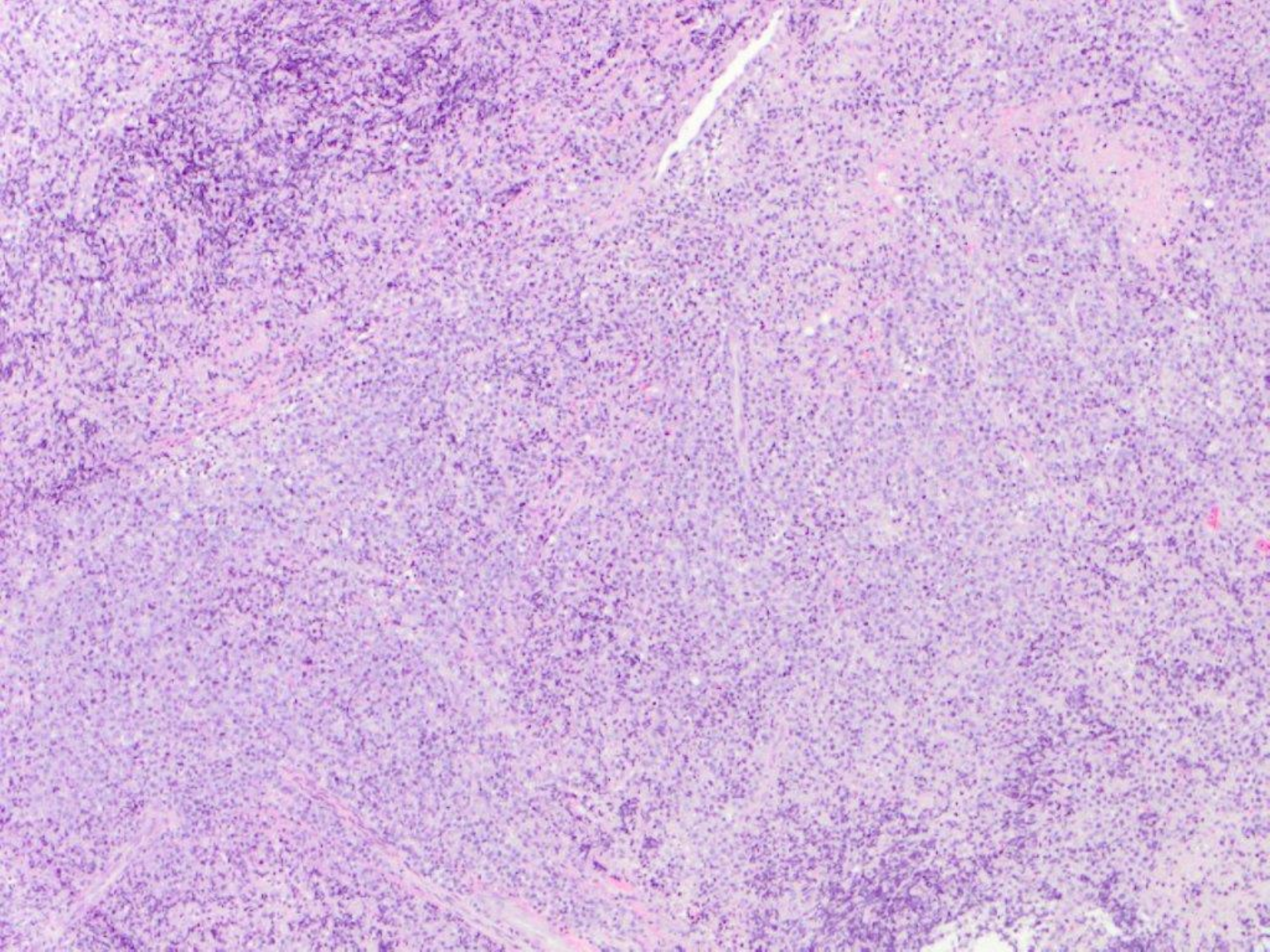


benign mixed tumor (pleomorphic adenoma)

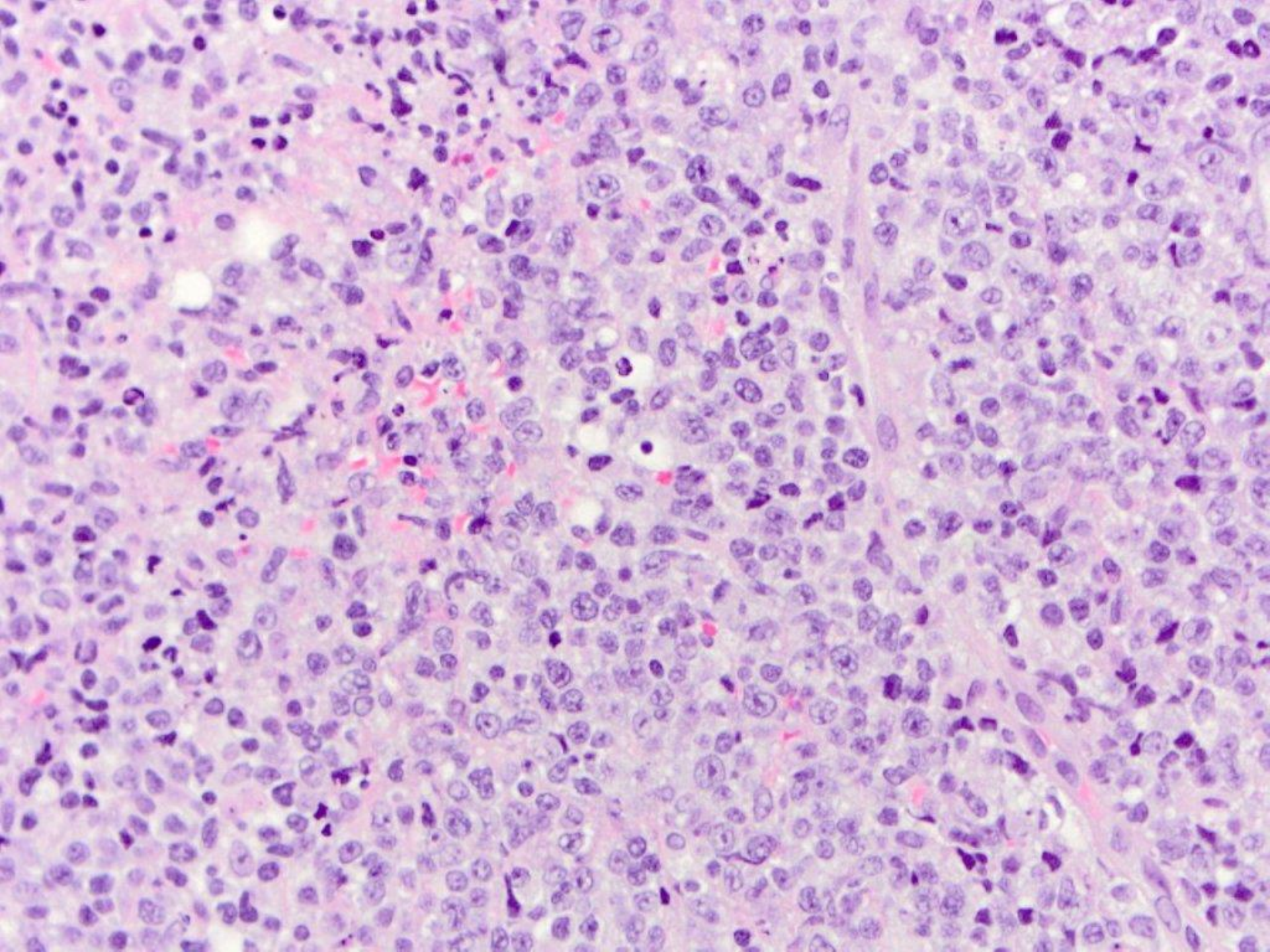




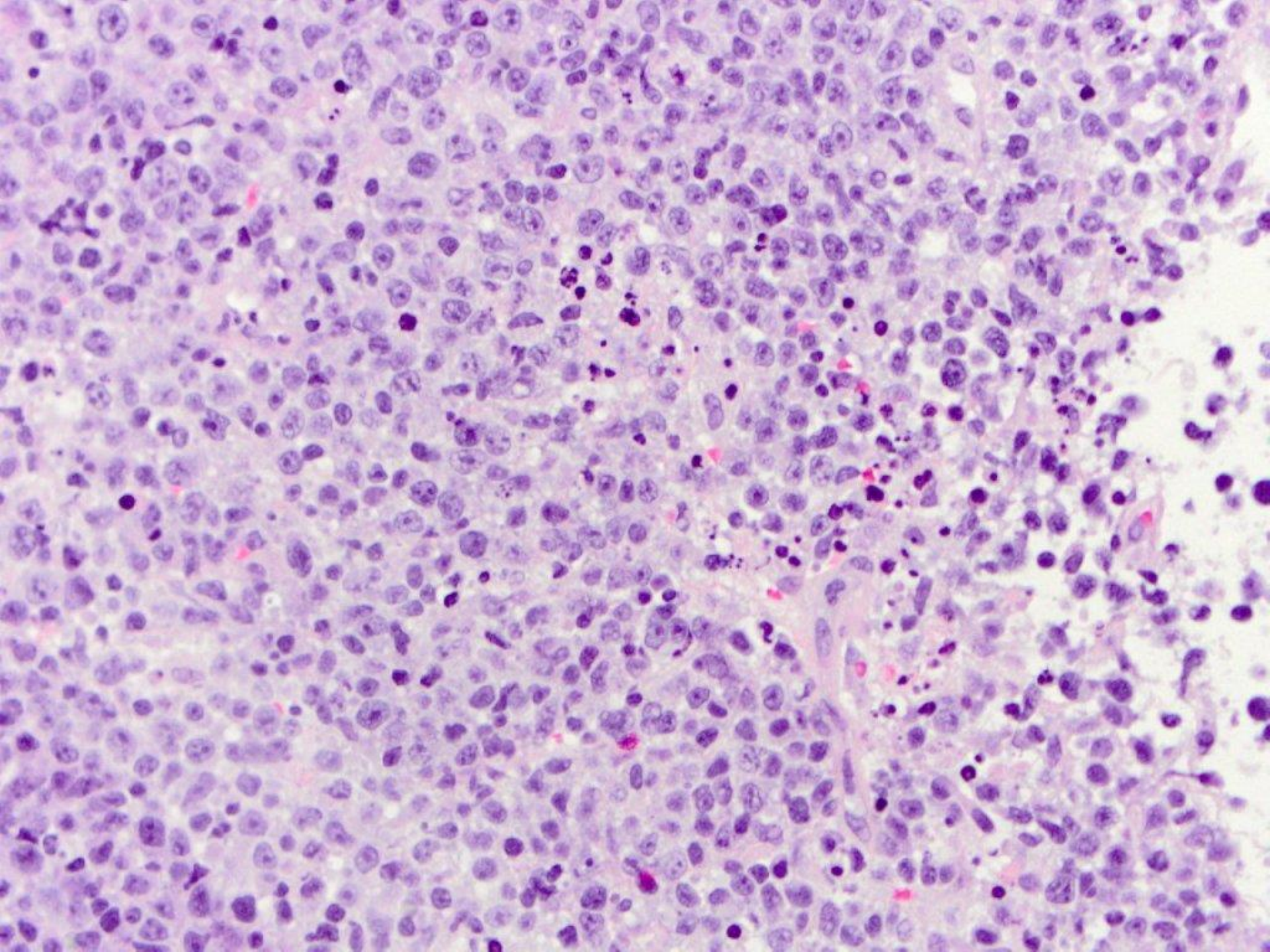




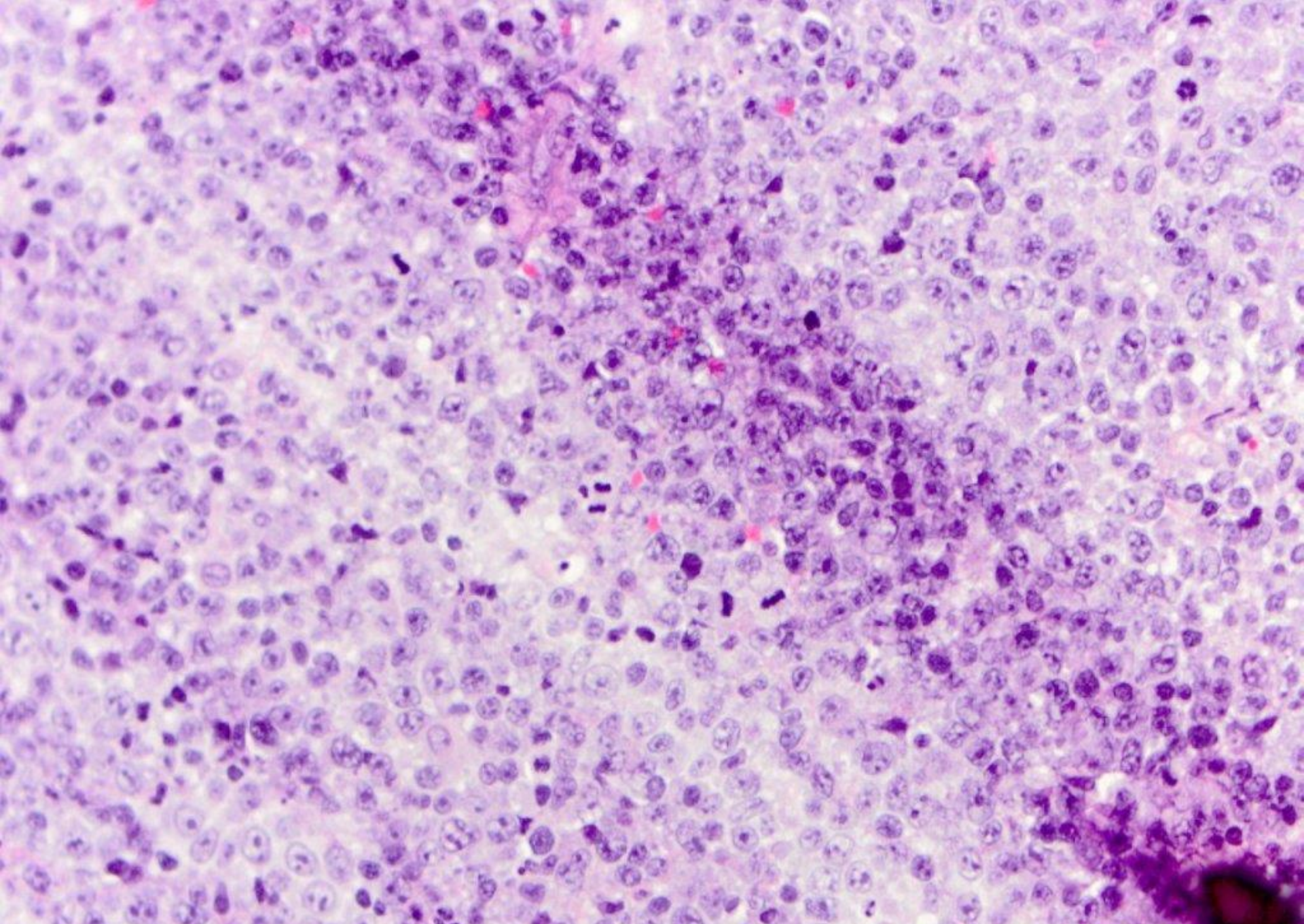






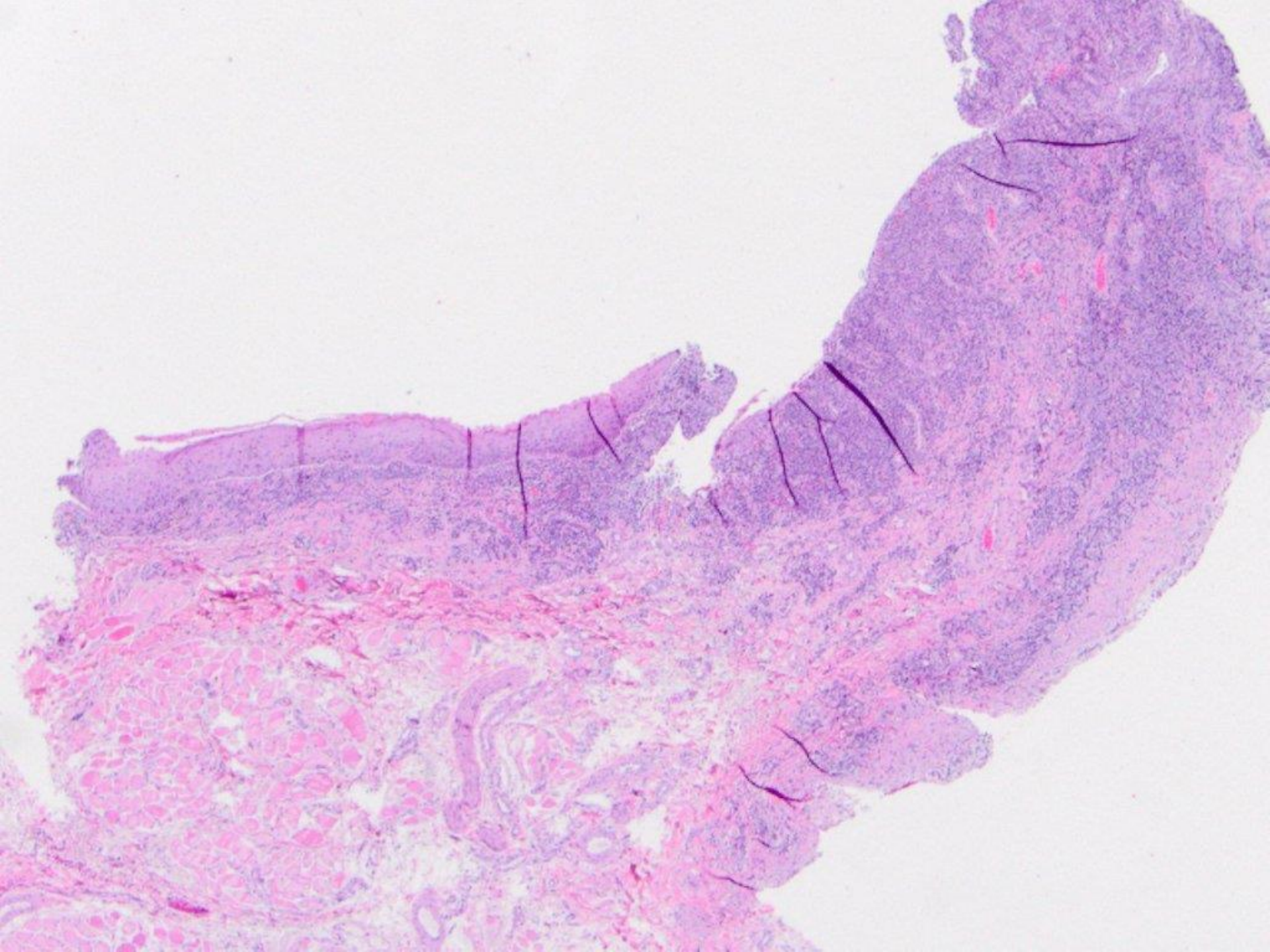




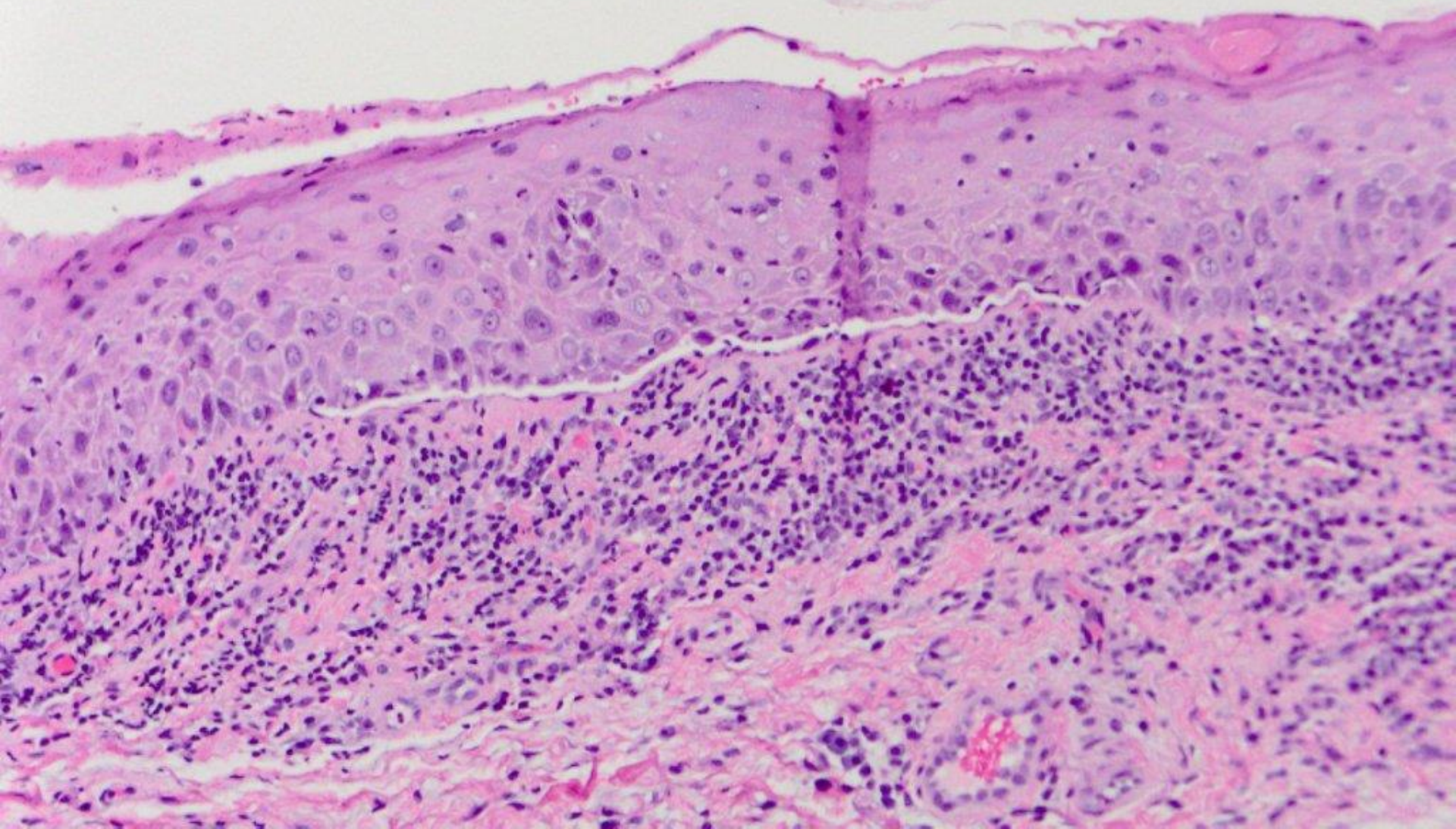


lymphoma

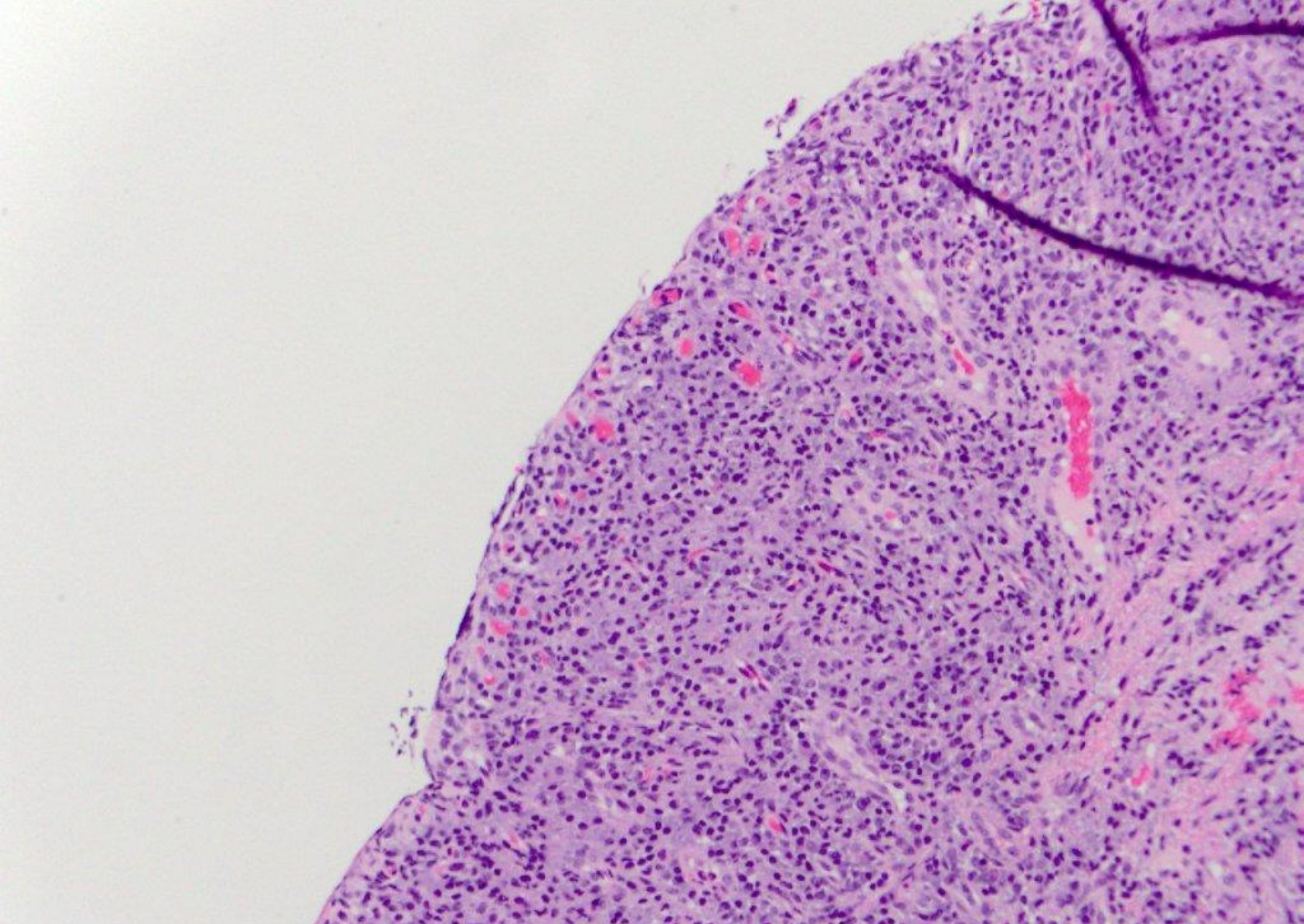






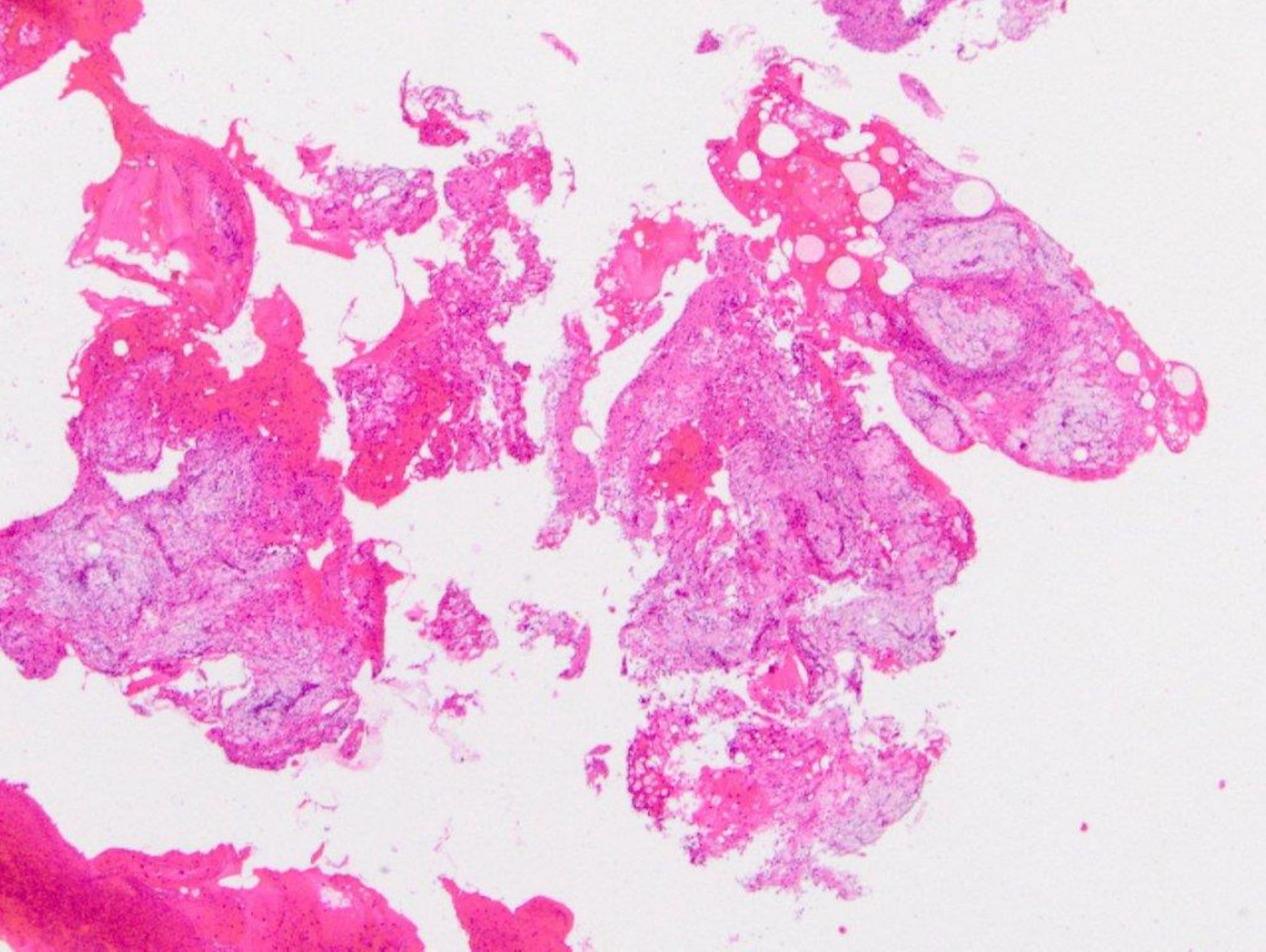




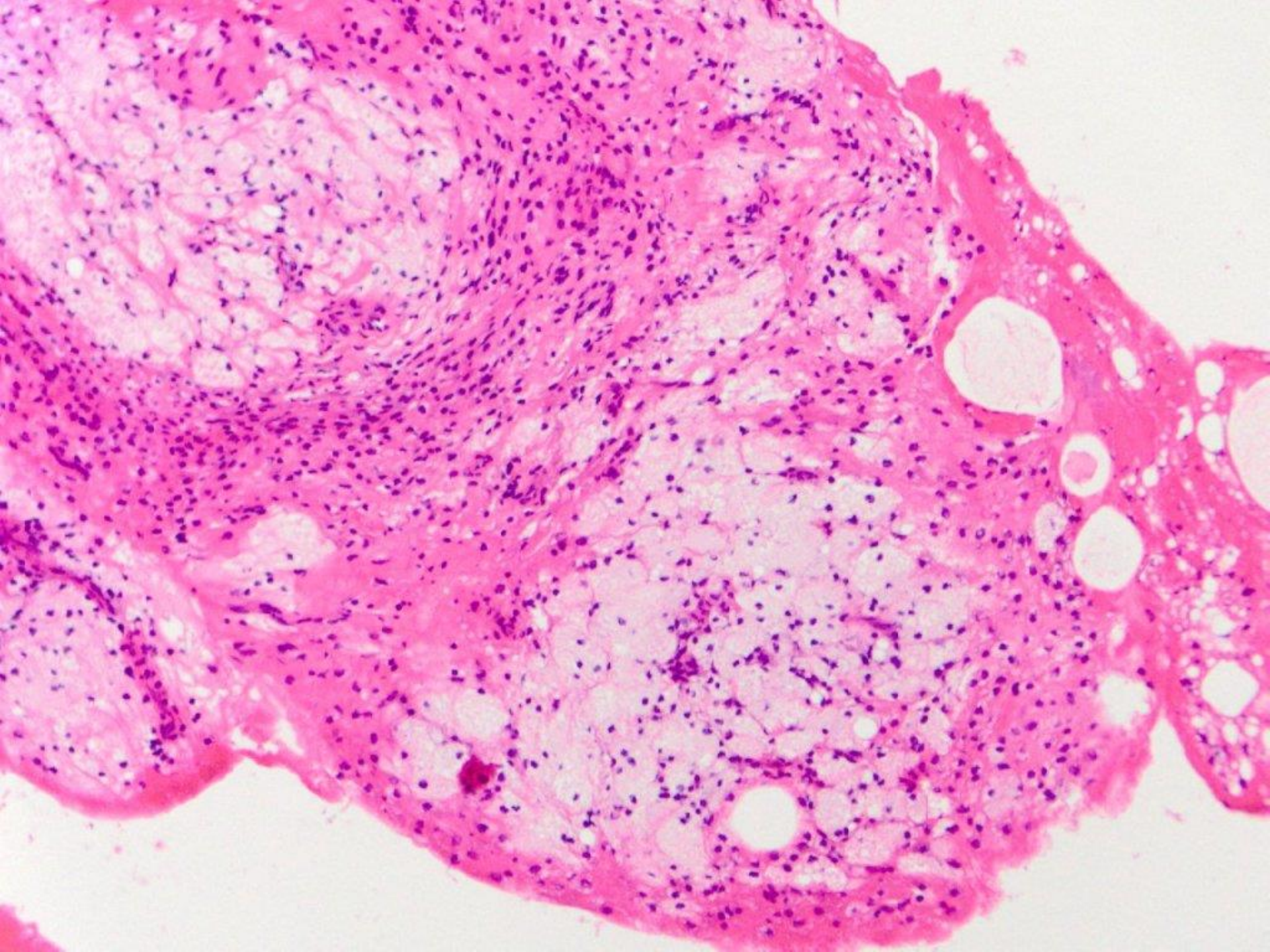


suggestive of pemphigoid

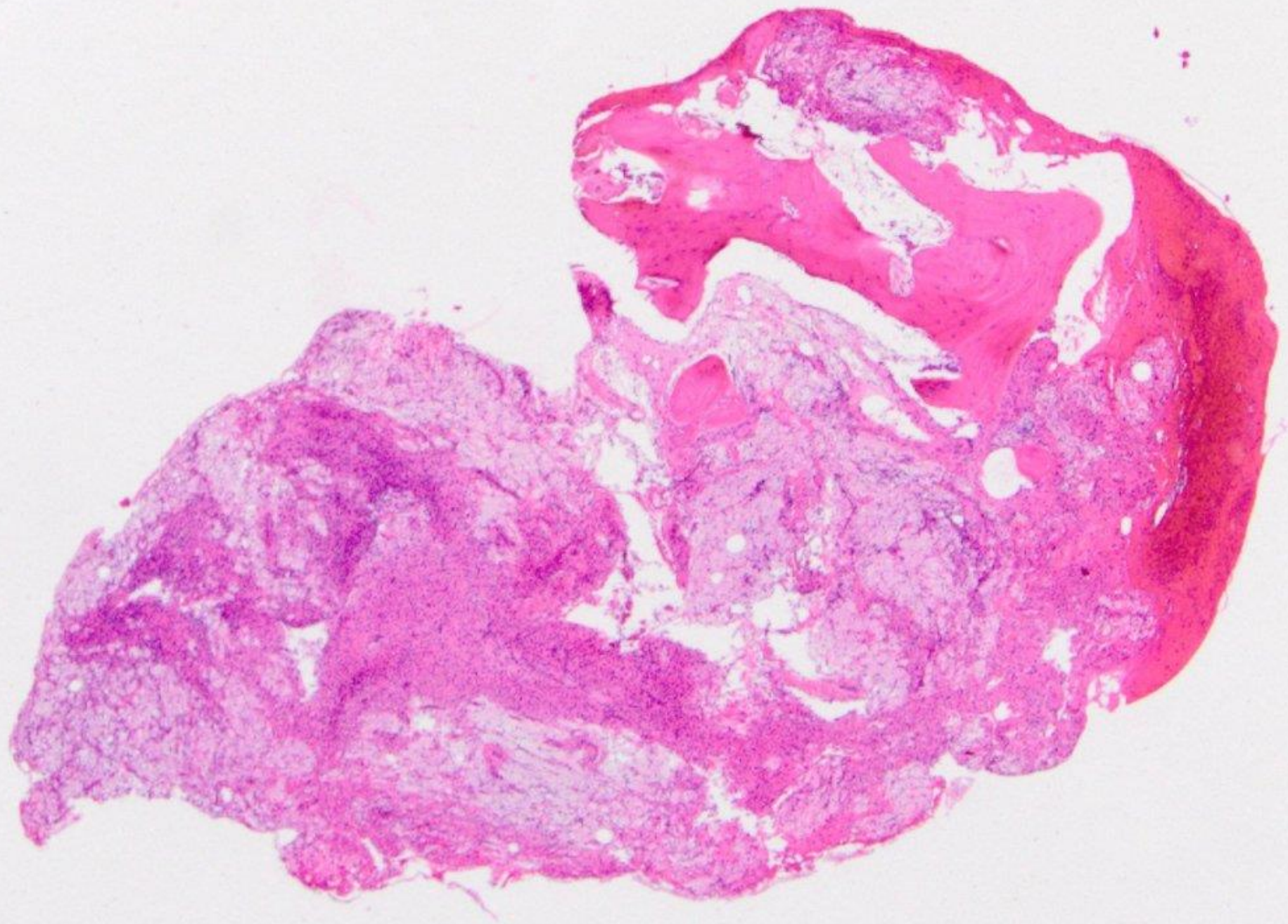




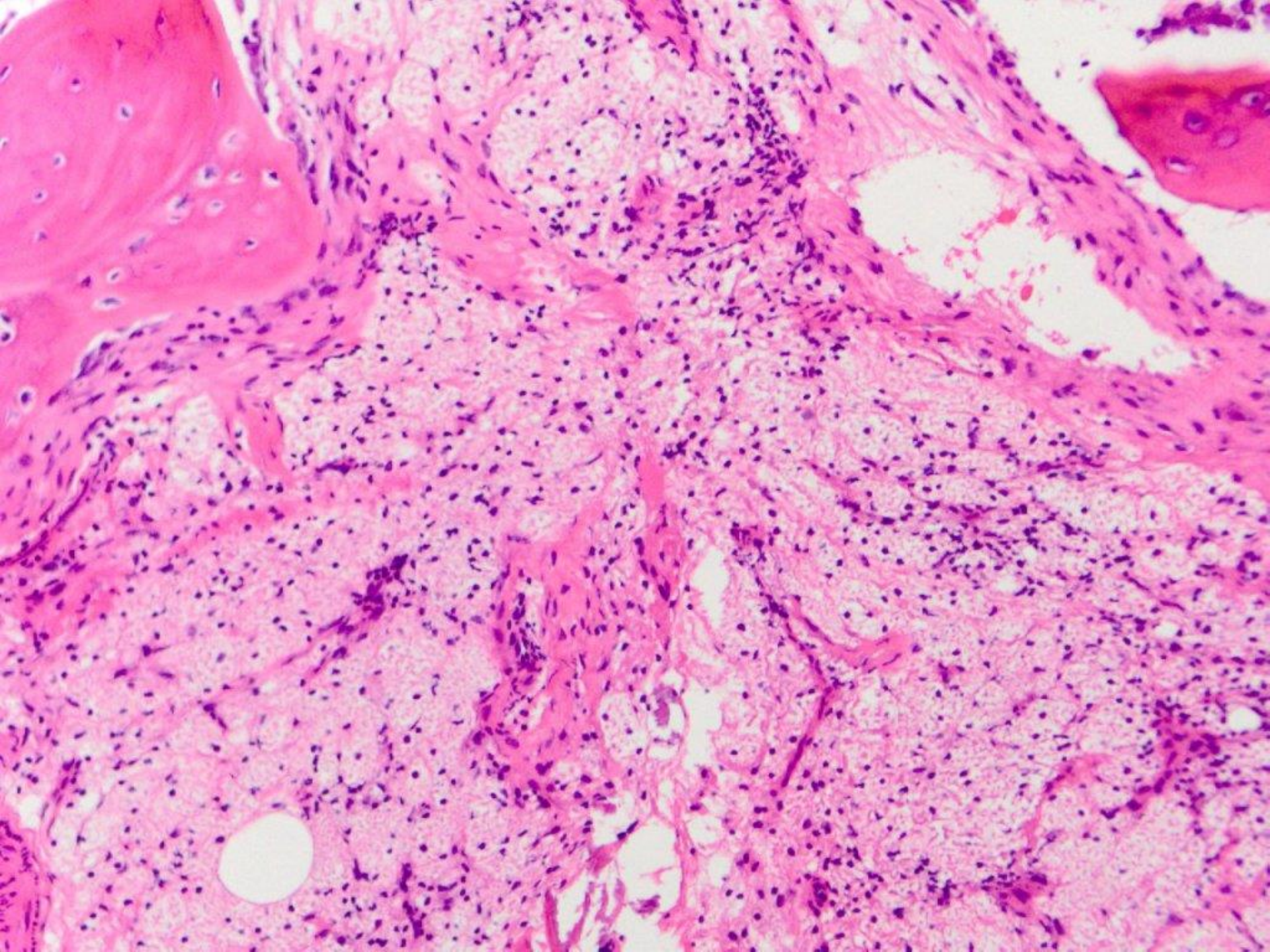




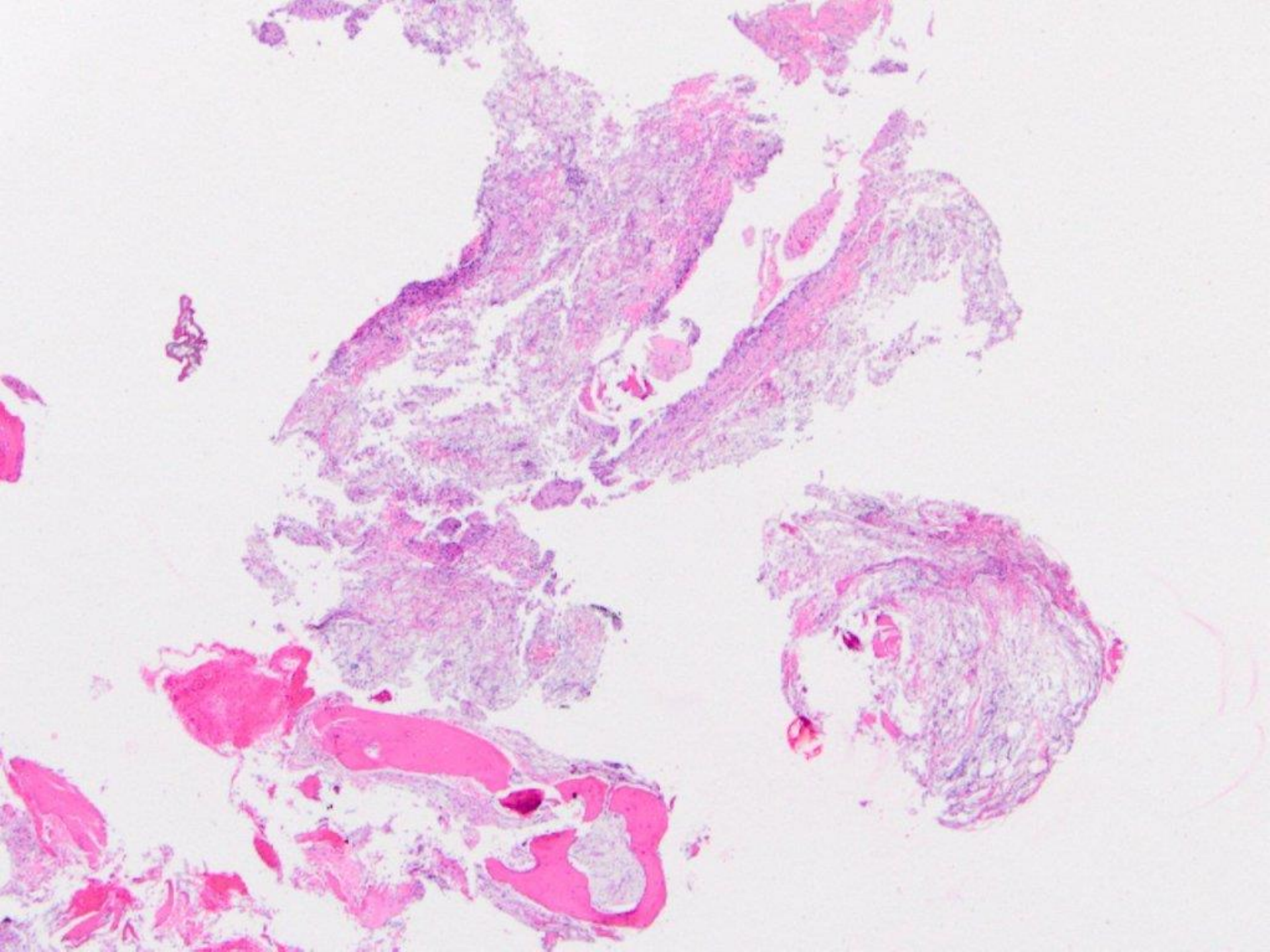




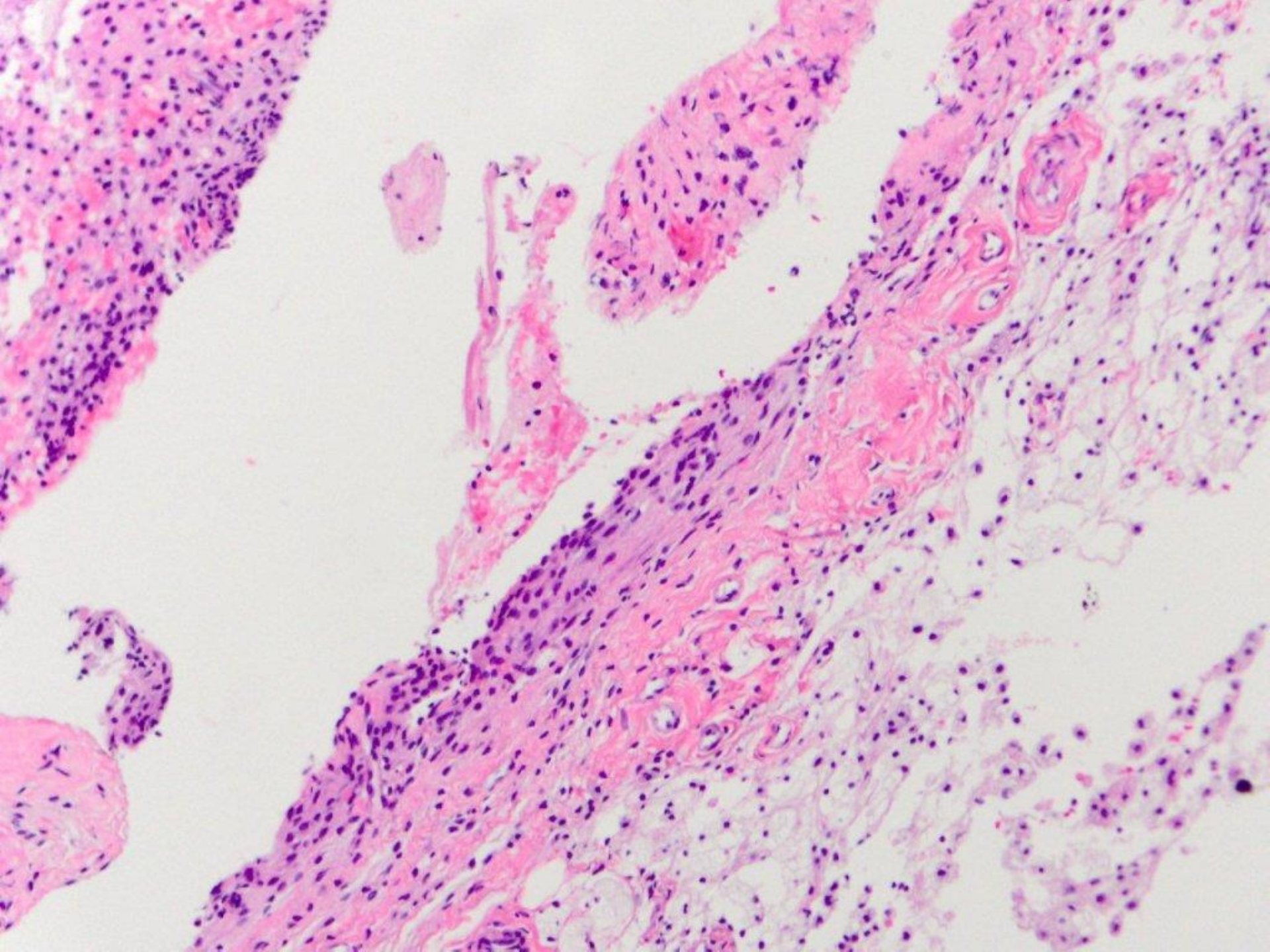




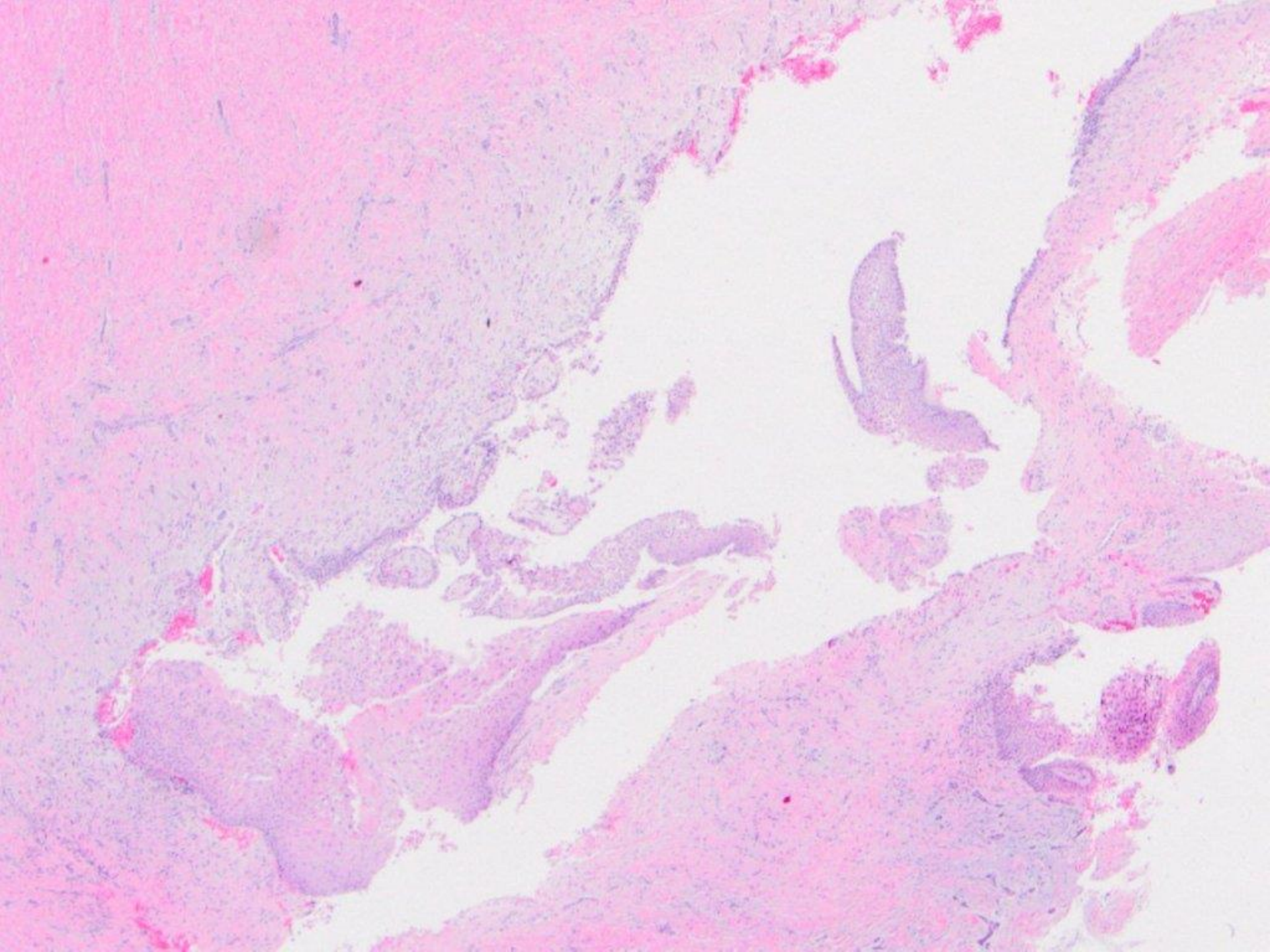




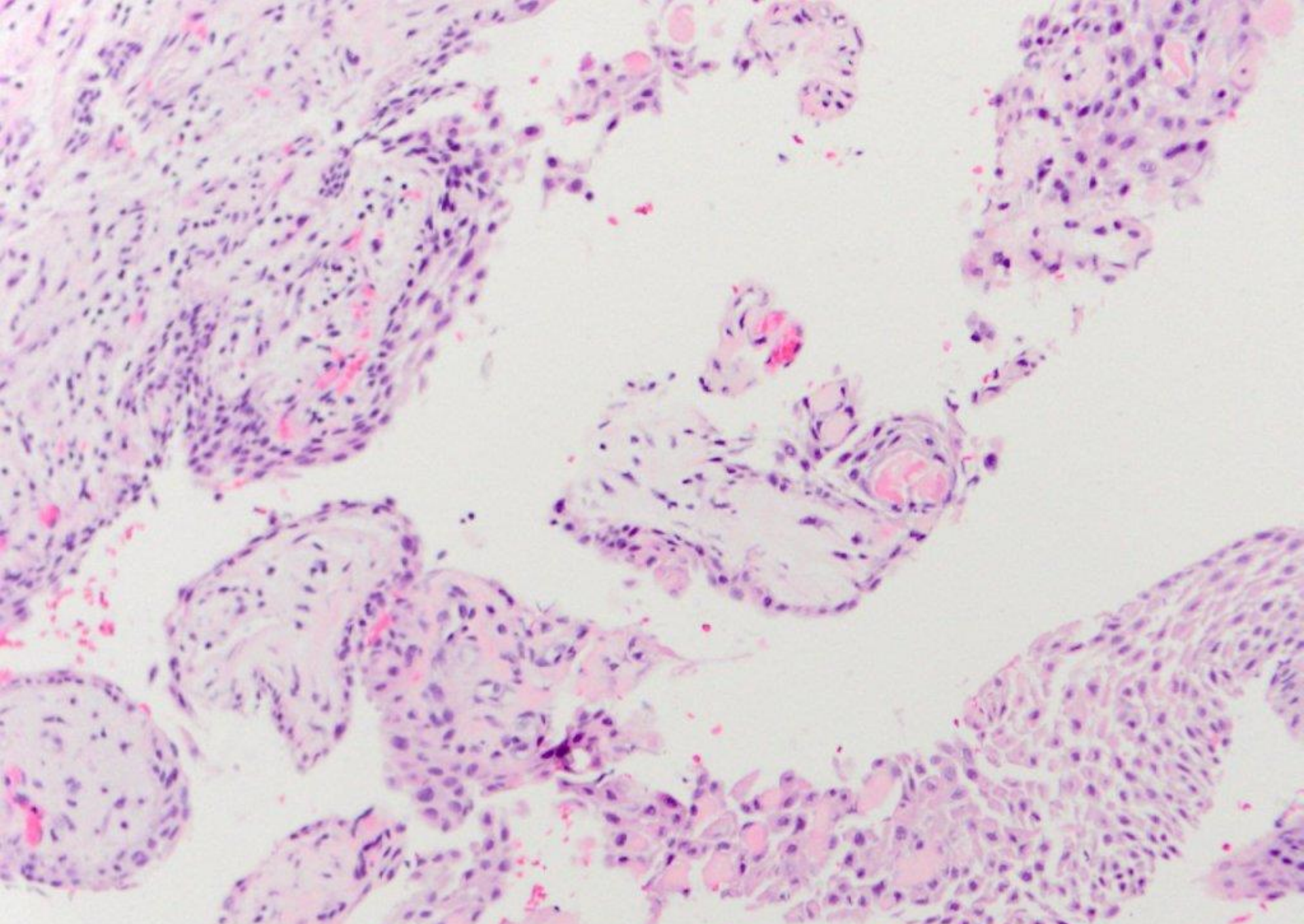












Odontogenic cyst; multiple histiocytes/xanthoma cells